


illuminating Recovery Pathways:

**Magnetic Resonance Tractography in
Neuroprognostication and Bioethical
Decision-Making**


Jorge Carrizosa MD, MS, NVS

Bogotá, Colombia



Disclosures

Nothing to disclose.

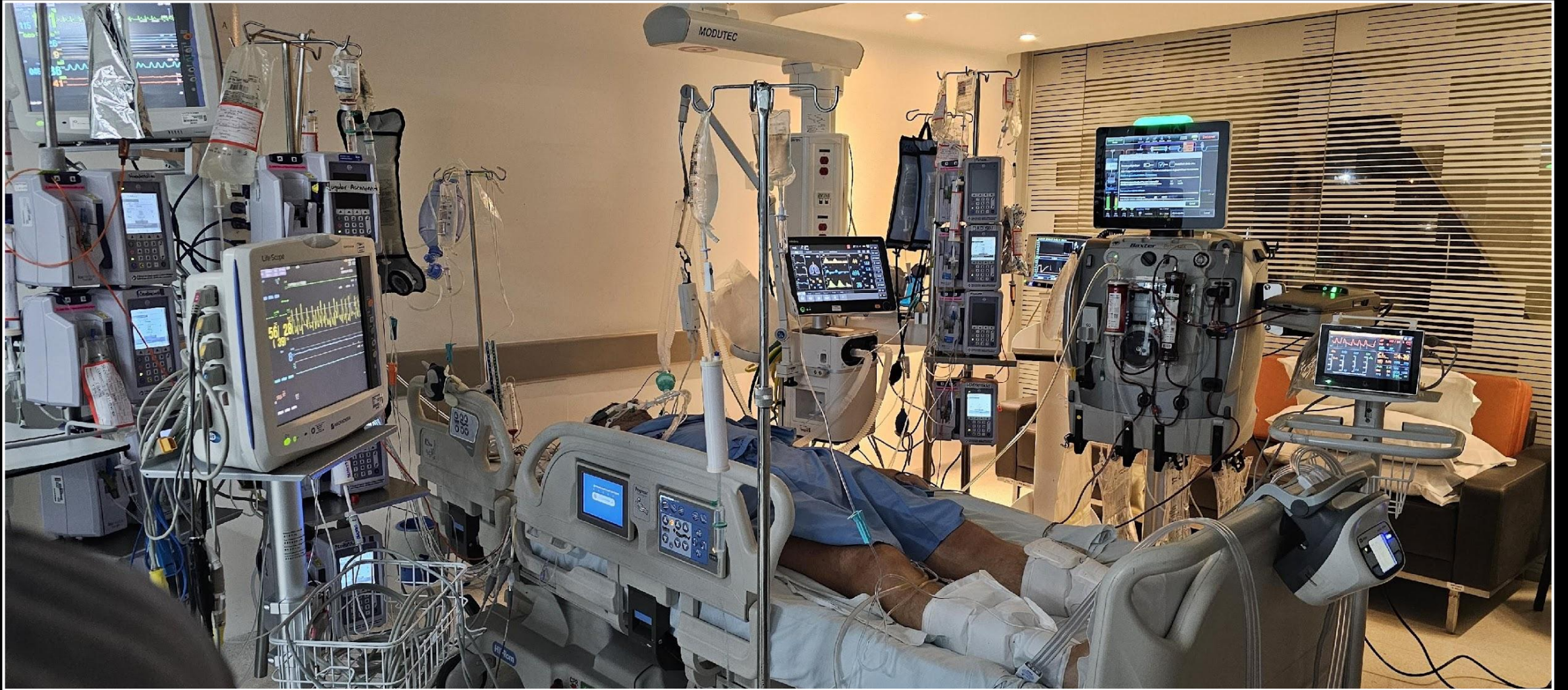

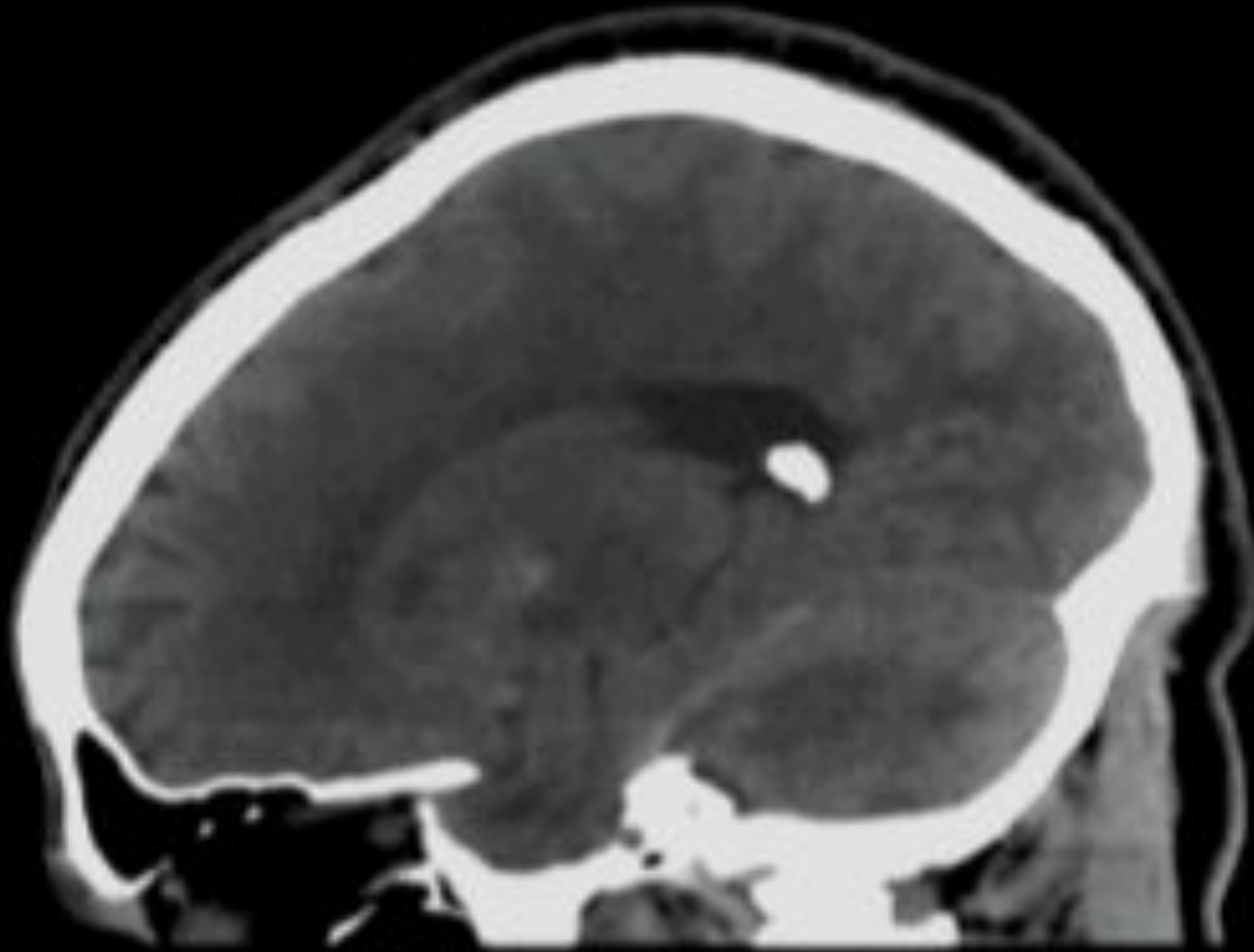


American Society of Neuroimaging - 49th Annual Meeting




American Society of Neuroimaging - 49th Annual Meeting

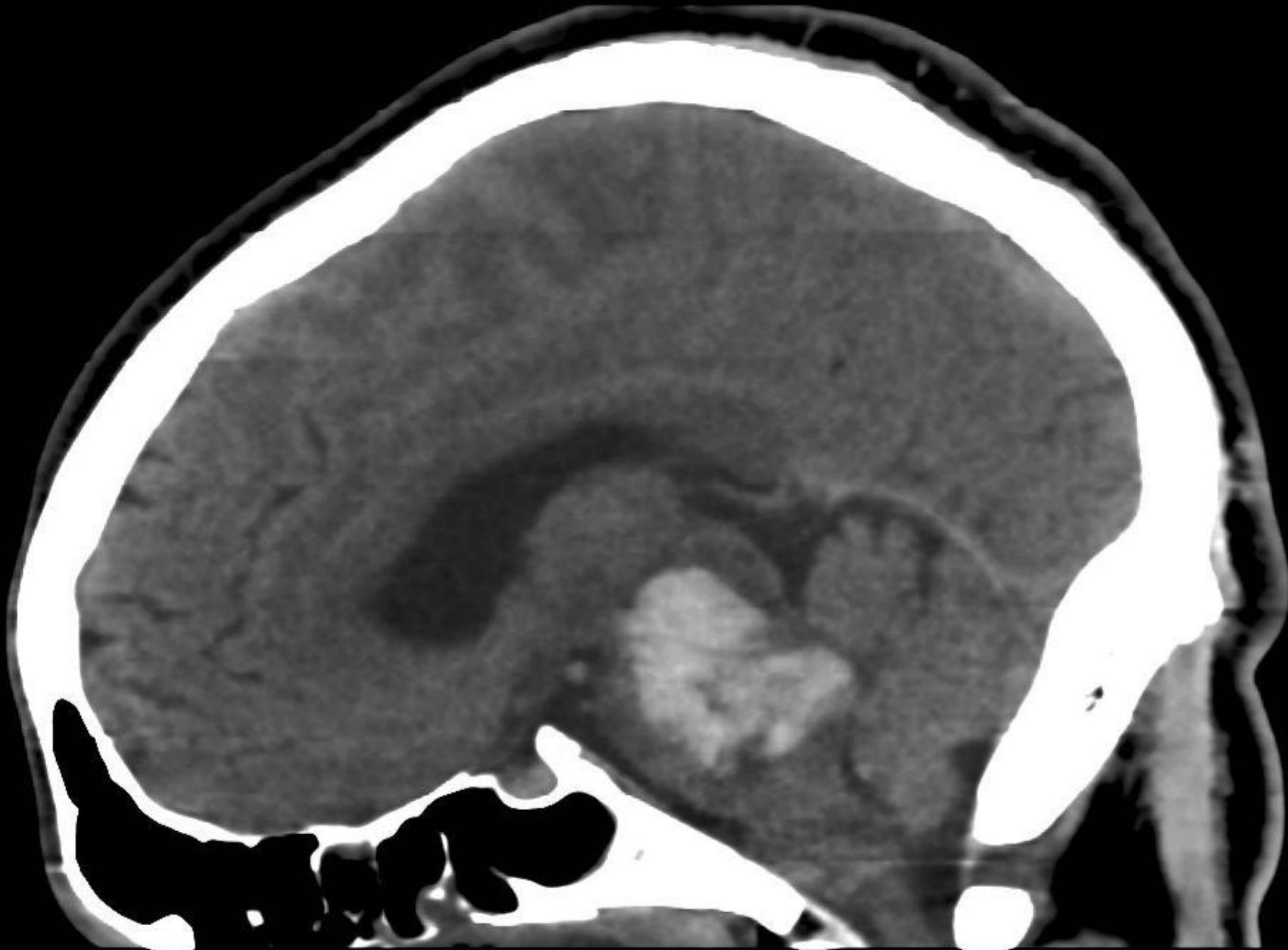




American Society of Neuroimaging - 49th Annual Meeting




R
A

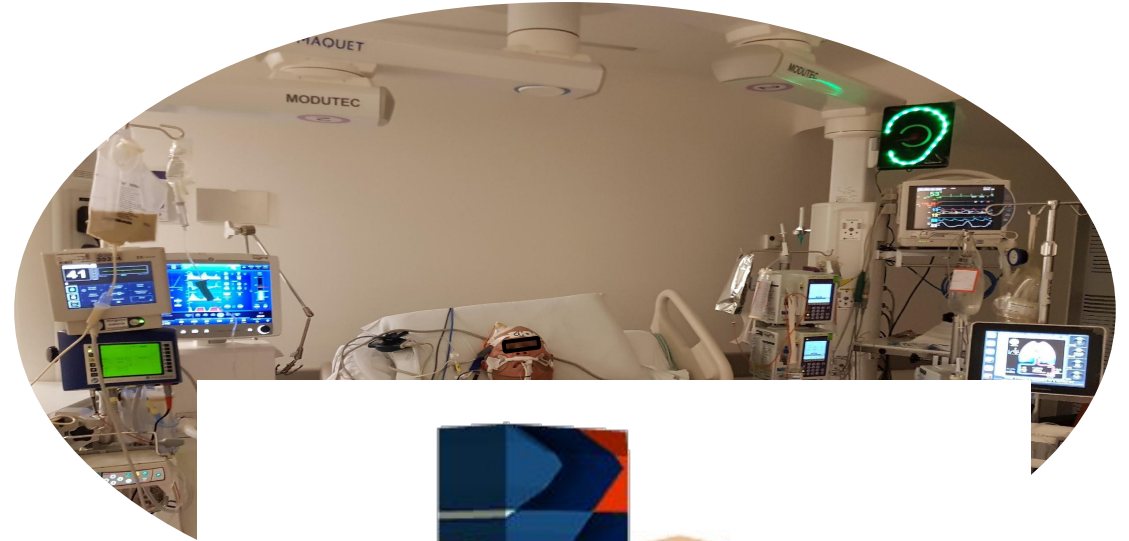



L
P

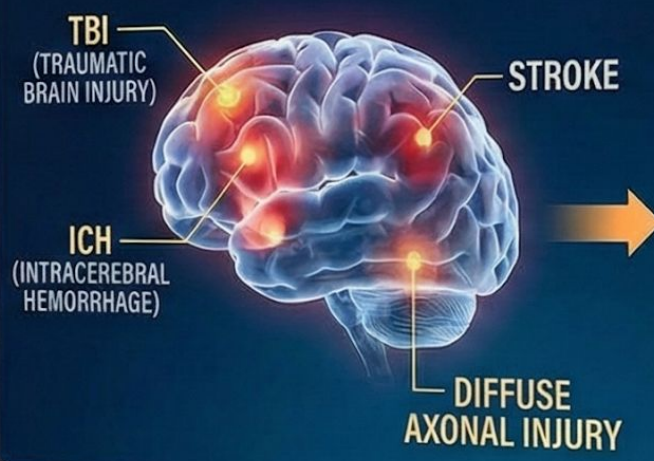
American Society of Neuroimaging - 49th Annual Meeting



Schrödinger's ICU?



PERSISTENT DISORDERS OF CONSCIOUSNESS AFTER TBI, ICH, STROKE, DIFFUSE AXONAL INJURY



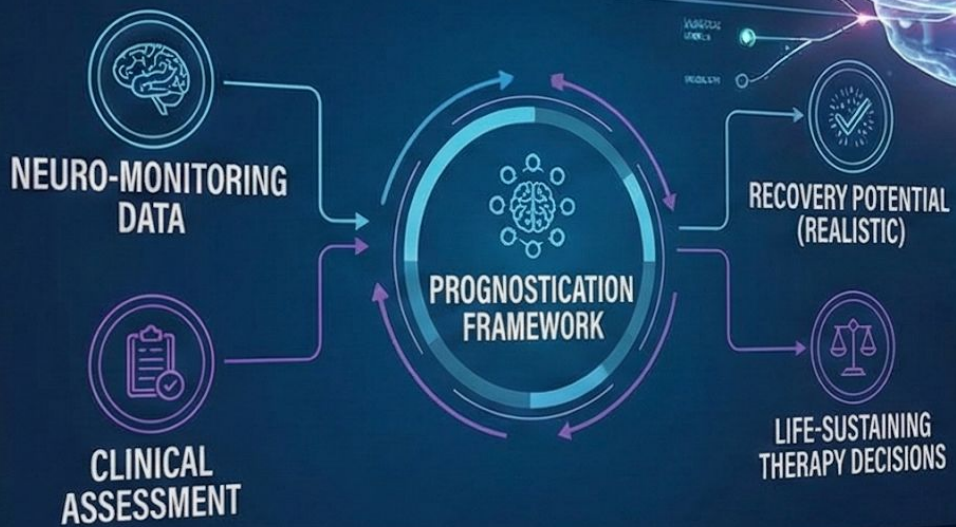
CONVENTIONAL EXAMINATION
AND CT IMAGING:
LIMITED PROGNOSTIC CERTAINTY

This block contains three icons representing conventional medical examinations: a reflex hammer, an eye chart with various letters (E, F, P, T, O, Z, L, P, F, D, P, D, Y, C, E, P), and a CT scan slice of a brain with a large question mark in the center. Above the icons is a yellow warning triangle with an exclamation mark.


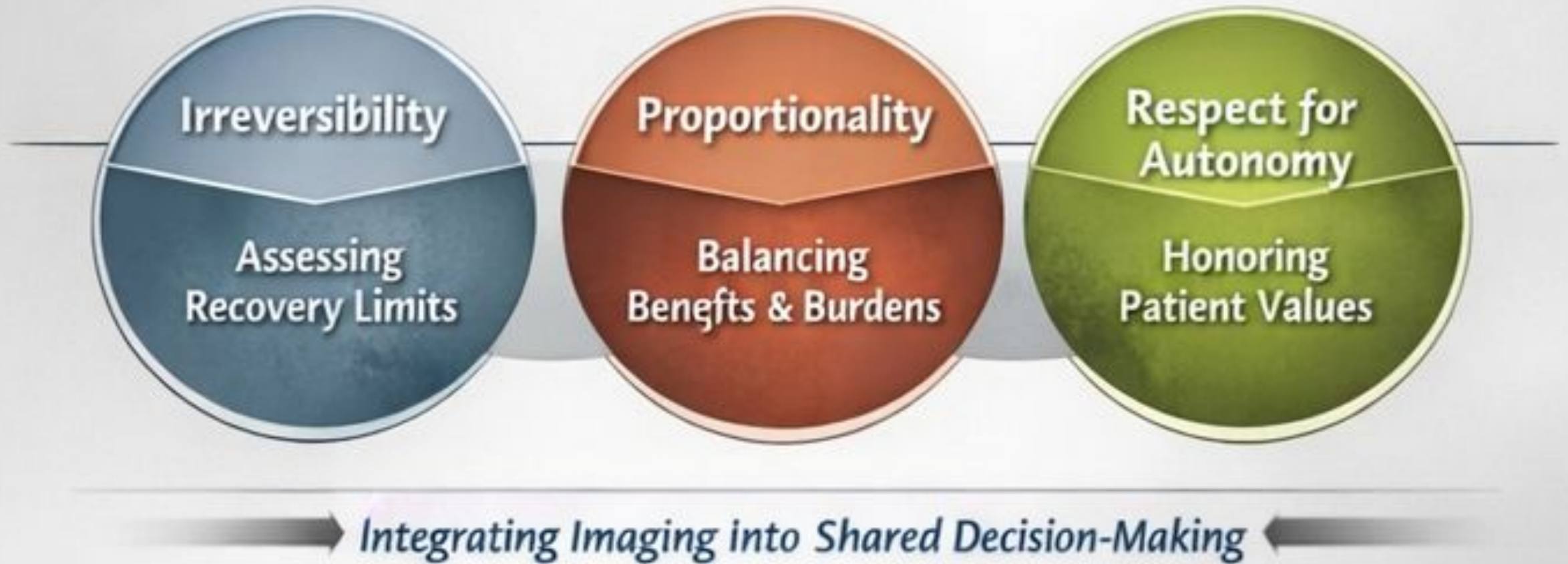


WHY PROGNOSTICATION DEFINES NEUROCRITICAL CARE:

Decisions about life-sustaining therapy depend on realistic recovery potential.



Bioethical Framework in Neuroprognostication



ILLUMINATING RECOVERY PATHWAYS

01

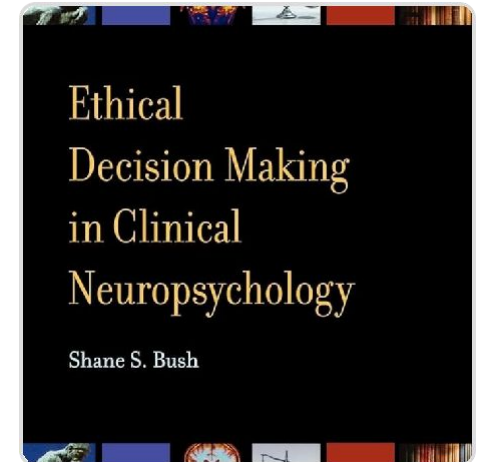
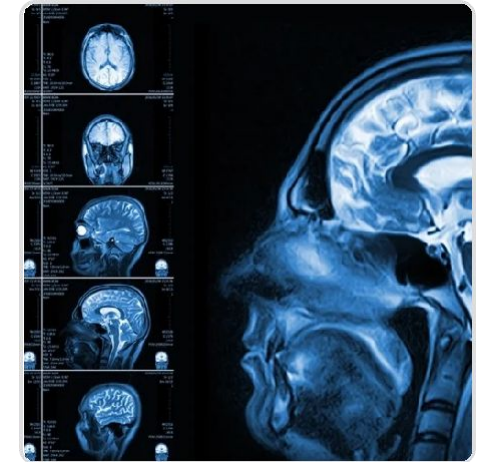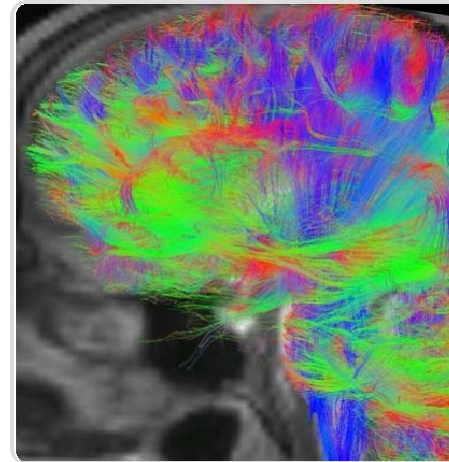
MRT for Neuroprognostication

Magnetic Resonance Tractography (MRT) is pivotal in neuroprognostication, assessing global white matter damage in patients with disorders of consciousness from focal brainstem injuries.

02

Aiding Bioethical Decisions

This advanced imaging helps illuminate recovery paths, aiding in bioethical decision-making.

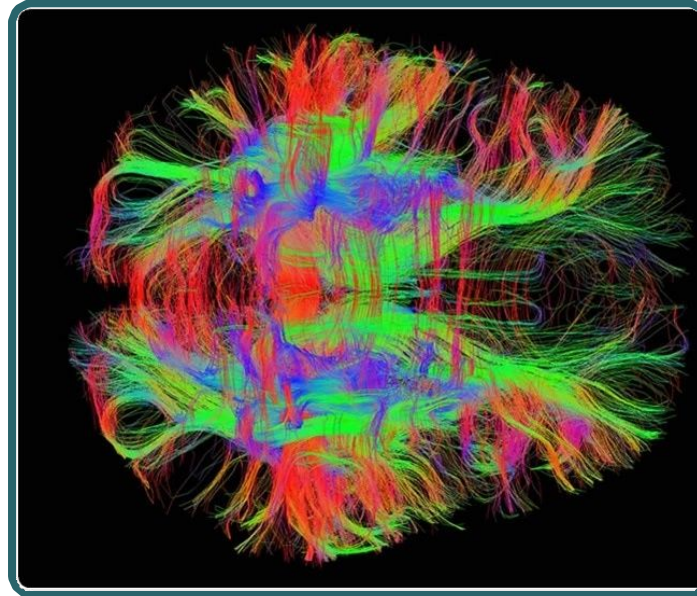

DIFFUSION MRI TRACTOGRAPHY: A WINDOW INTO CONNECTIVITY

DTI Principles

Diffusion Tensor Imaging (DTI) measures water molecule diffusion along white matter tracts. Key metrics include **FA (fractional anisotropy)** and **MD (mean diffusivity)**.

Tractography enables **non-invasive visualization** of structural connectivity, which is vital for mapping consciousness networks.




Tractography offers a non-invasive window into structural connectivity, enabling the mapping of critical **neural pathways and consciousness networks**.

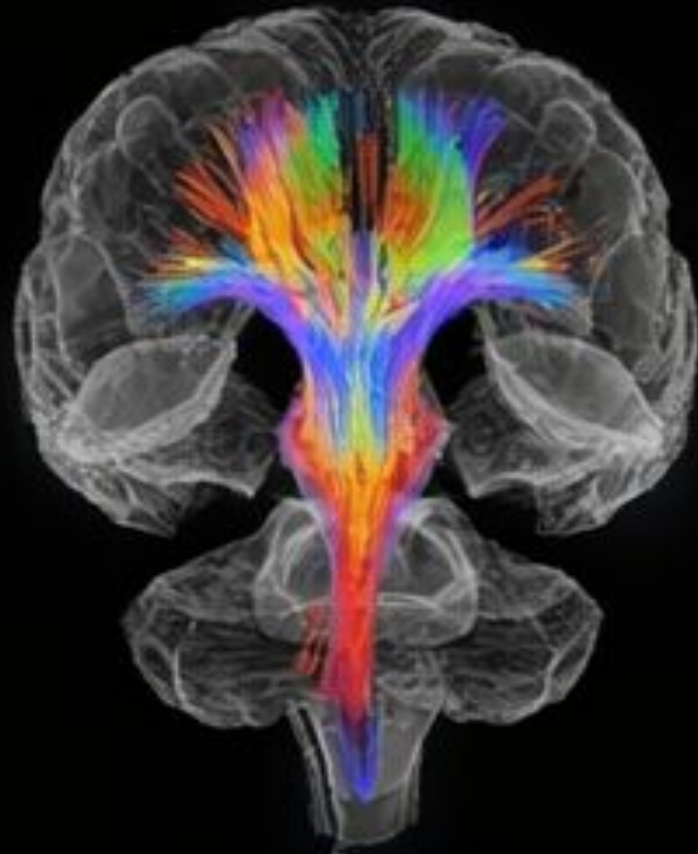
Clinical & Analytical Advances

Recent breakthroughs include the use of **real-time ICU applications** and high-resolution imaging from advanced 3T MRI systems for better diagnostics.

Analysis is now significantly enhanced by **AI and machine learning algorithms**, improving the detection and mapping of neural pathways.

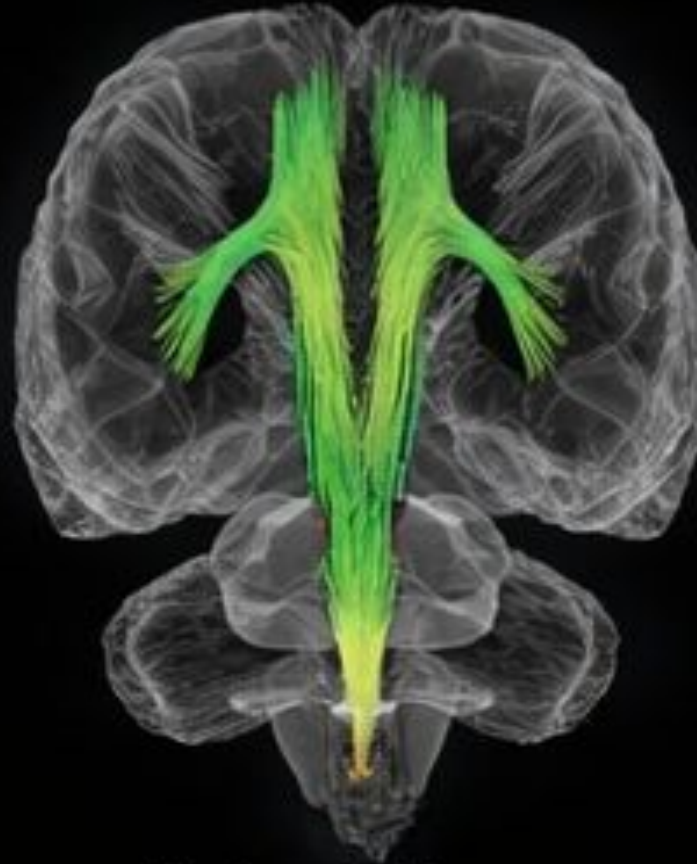

Key White Matter Pathways in Severe Brain Injury

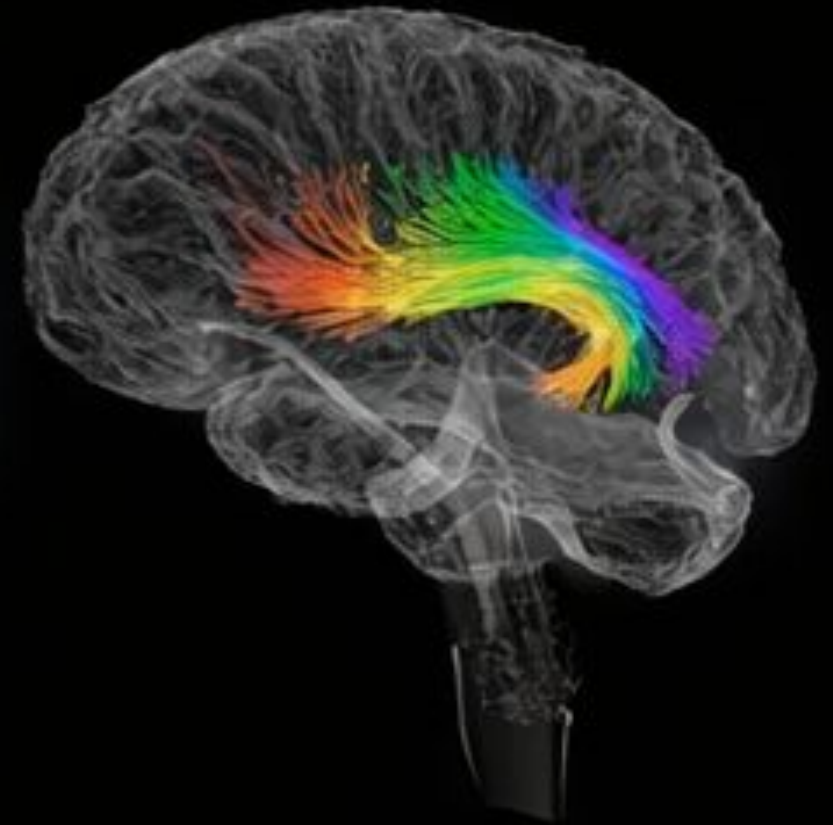

**Arousal Pathway
(ARAS)**

Ascending Reticular Activating System




**Motor Pathway
(Corticospinal Tracts)**



**Language Pathway
(Arcuate Fasciculus)**

3D DTI Tractography of Arousal, Motor, and Language Networks



Tractography Findings and Prognostic Implications

ARAS Disruption

Corticospinal Tract Damage


Arcuate Fasciculus Injury

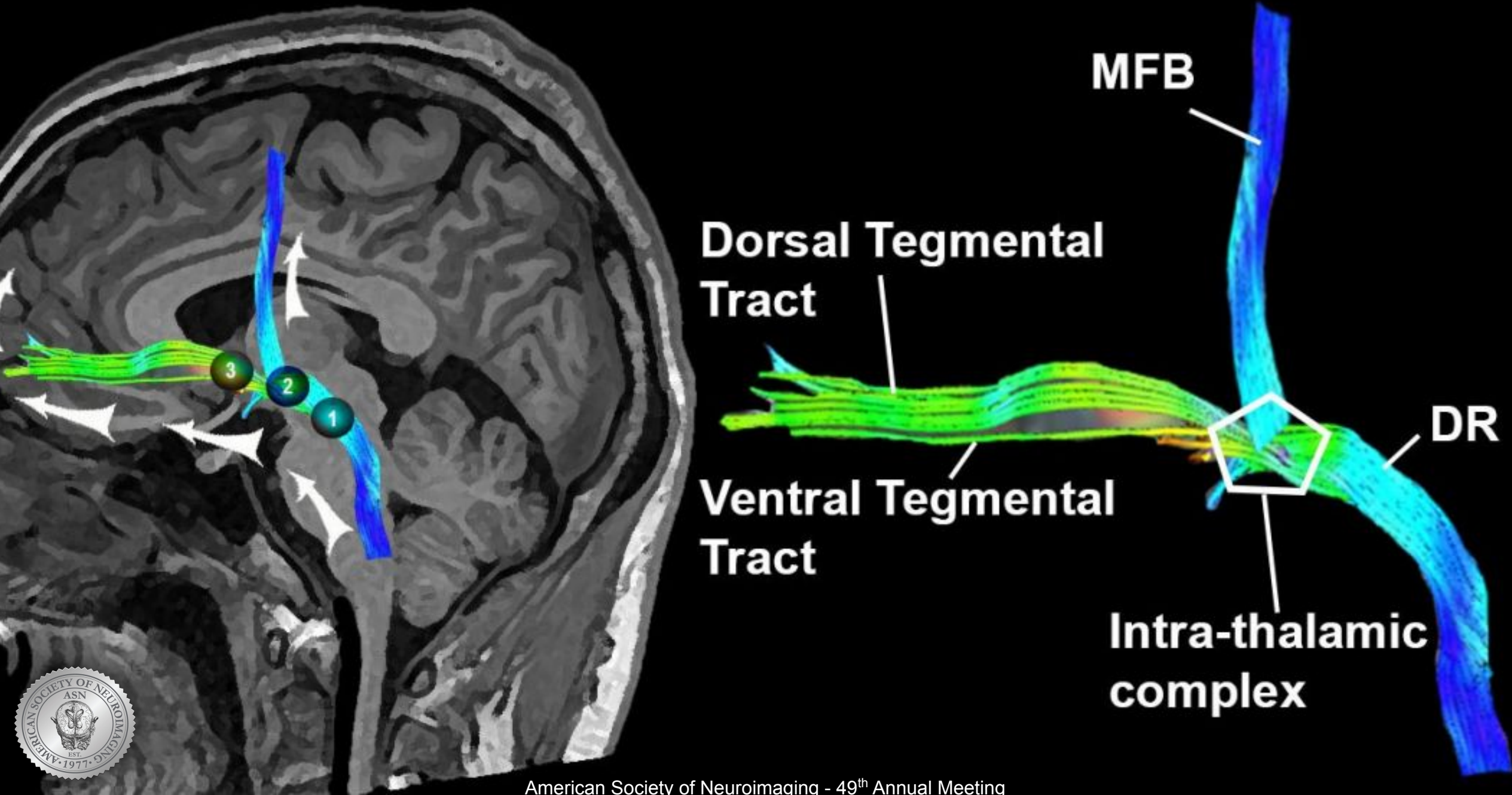
Persistent
Coma / UWS


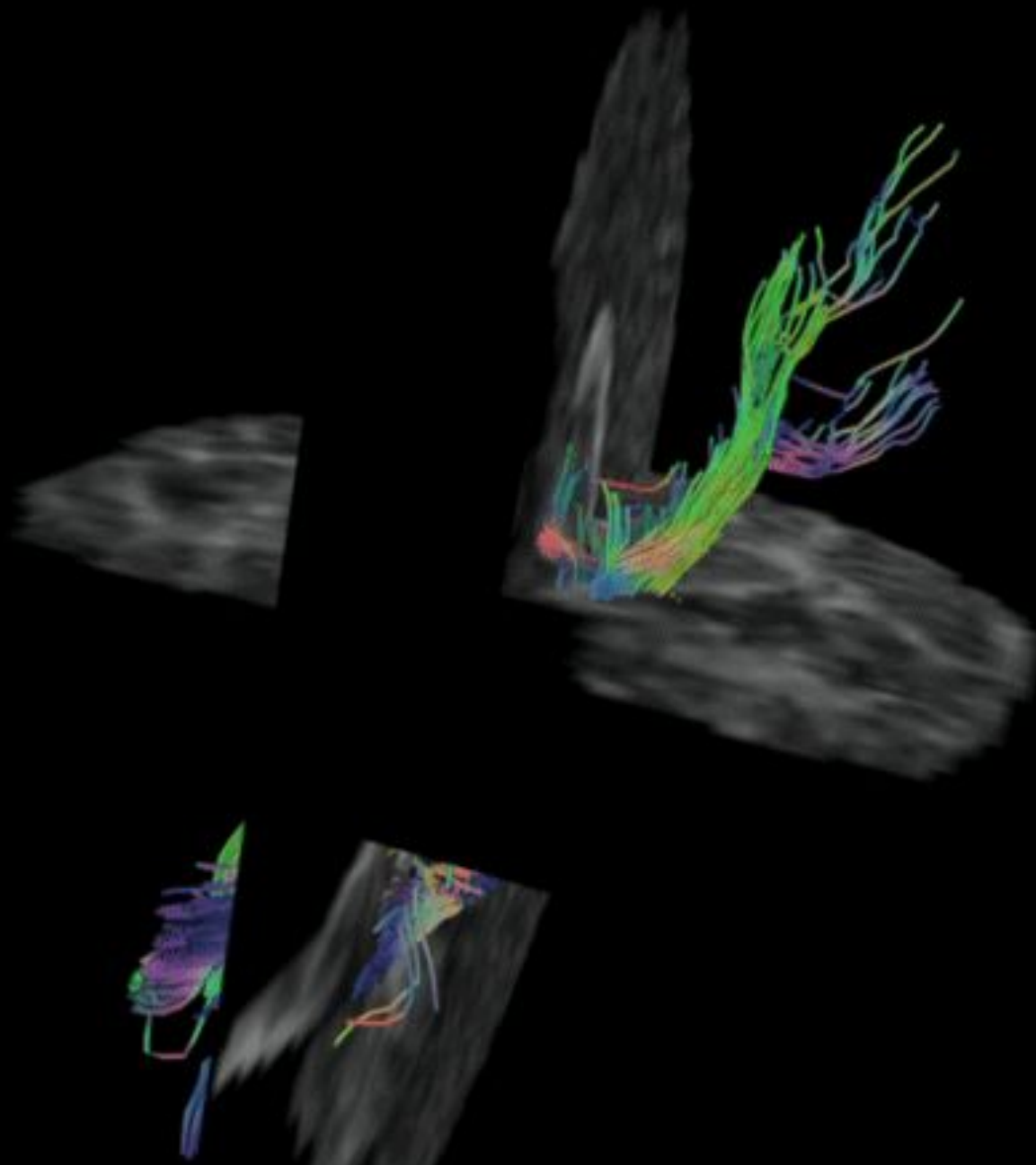
Quadriparesis

Irreversible
Aphasia

Aligning Imaging Findings with Clinical Outcomes










American Society of Neuroimaging - 49th Annual Meeting

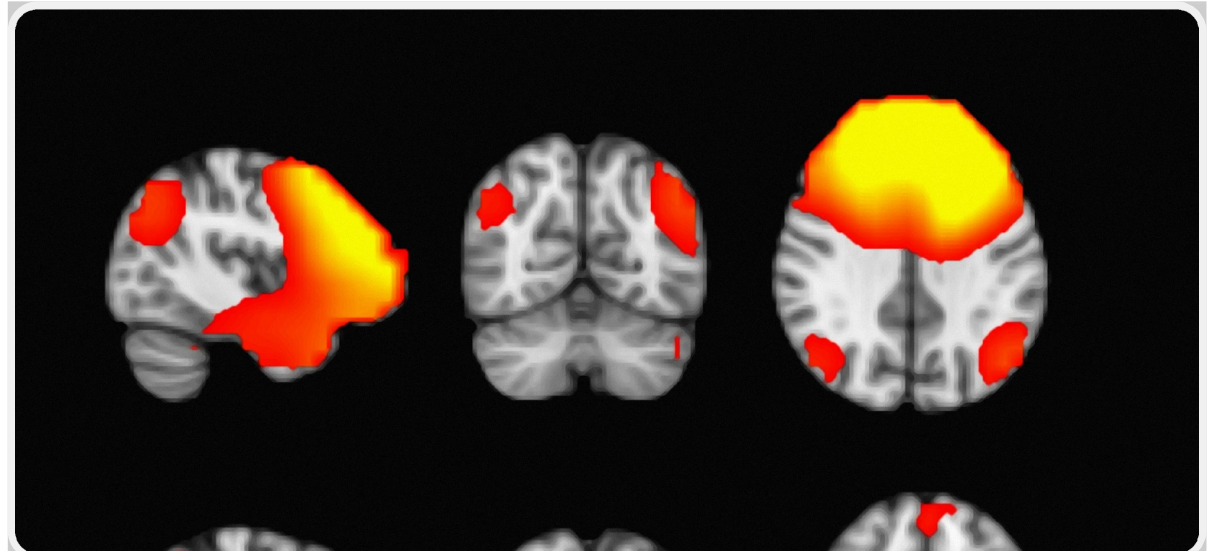



TRACTOGRAPHY IN NEUROPROGNOSTICATION

Default Mode Network

“The DMN may play a role in various facets of internal or self-directed thinking, featuring central nodes located in the posterior cingulate cortex and the medial prefrontal cortex,”

Egawa S, Ader J, Claassen J. Recovery of consciousness after acute brain injury: a narrative review. *J Intensive Care*. 2024 Sep 26;12(1):37. doi: 10.1186/s40560-024-00749-9.

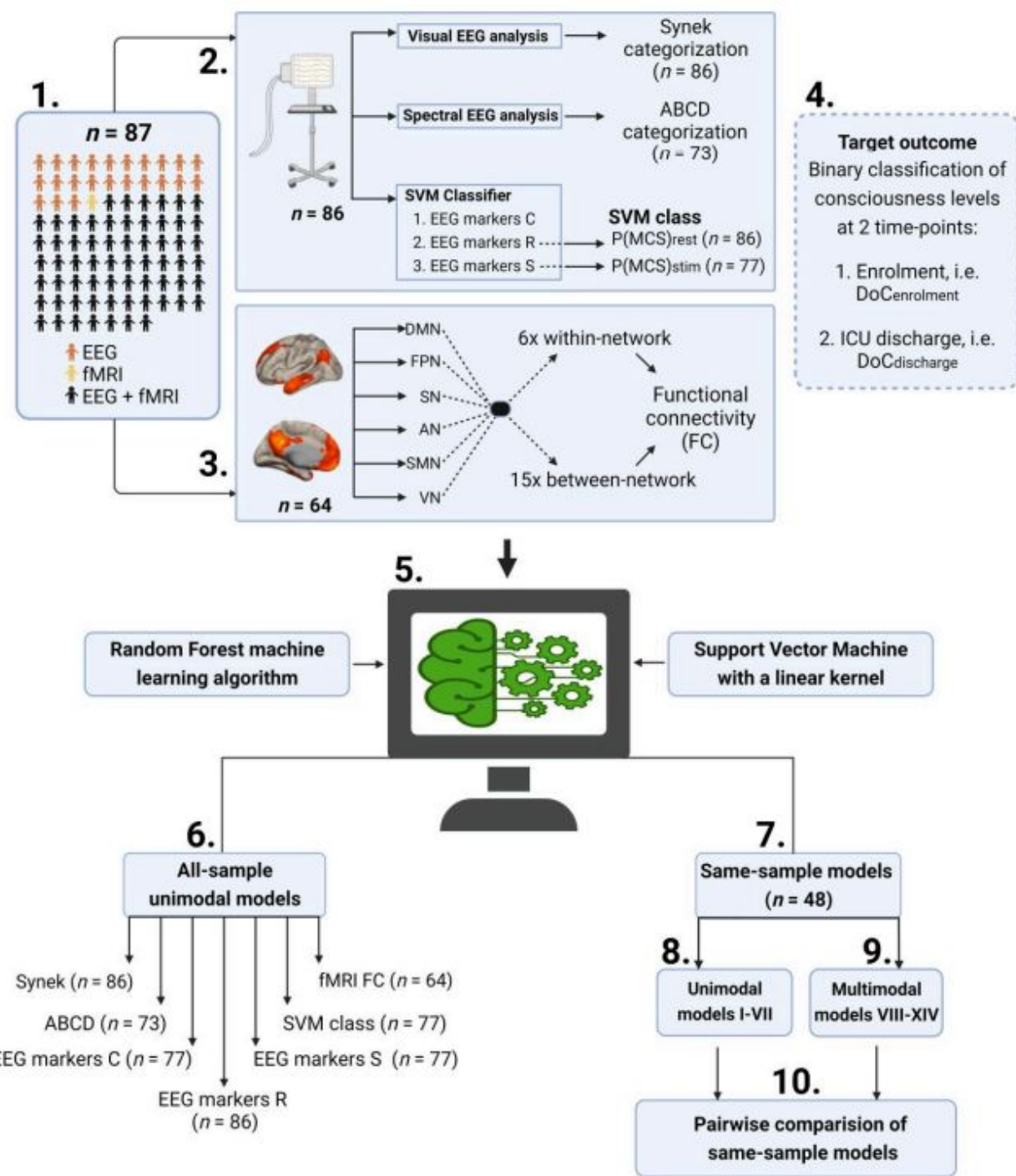


Prognostic Implications

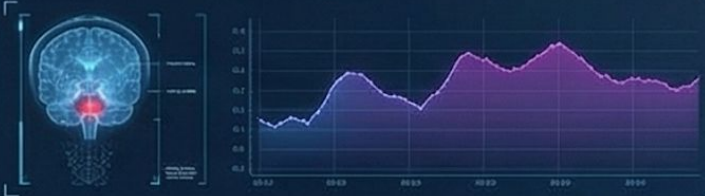
This multimodal approach is vital for neuroprognostication. The **preserved DMN offers hope for recovery**, while fMRI results clarify the patient's non-responsive state, guiding future clinical decisions.

Multimodal prediction of residual consciousness in the intensive care unit: the CONNECT-ME study

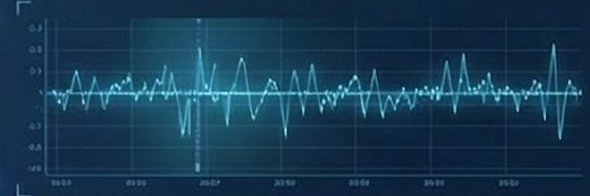Amiri M, Et Al. Brain. 2023 Jan 5;146(1):50-64. doi: 10.1093/brain/awac335.



NEUROPROGNOSTICATION: RESTING-STATE BOLD fMRI EVALUATION

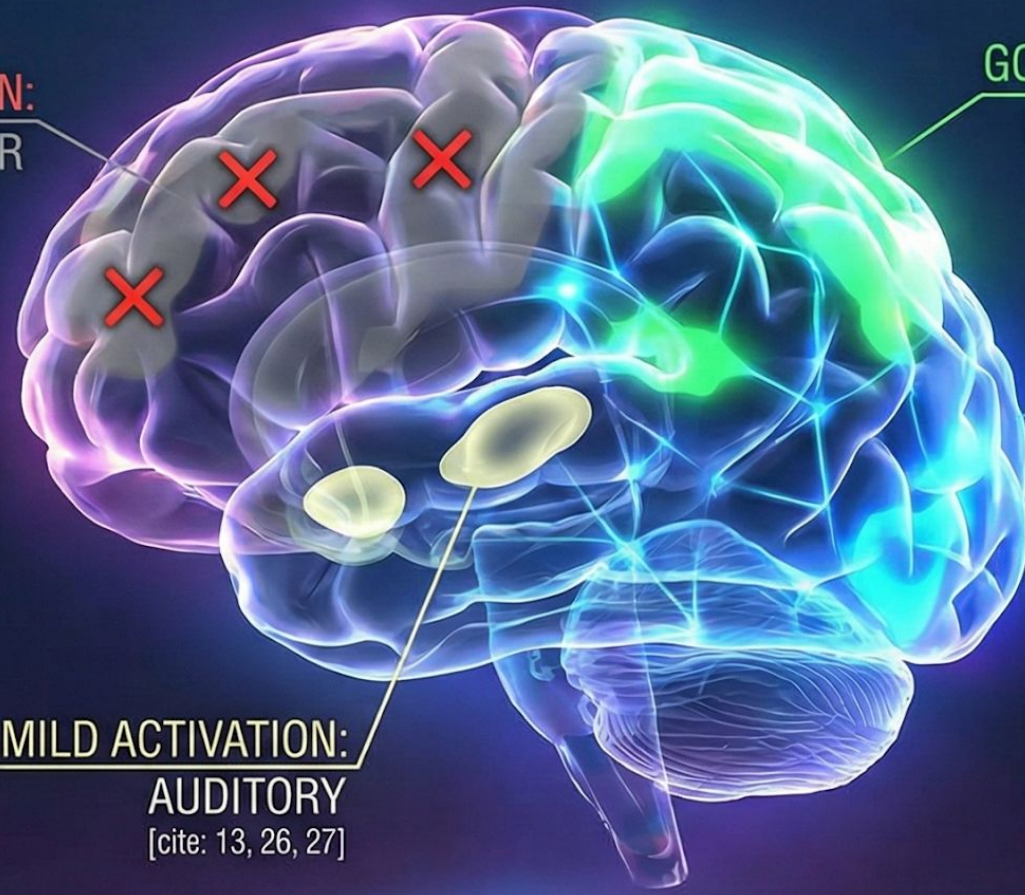


PATIENT: DAR
INDICATION: Minimal Consciousness vs. Locked-in Syndrome
ETIOLOGY: Midbrain Hemorrhage
TECHNIQUE: Resting-State BOLD (No Paradigms)



NO GOOD ACTIVATION:
LANGUAGE & MOTOR

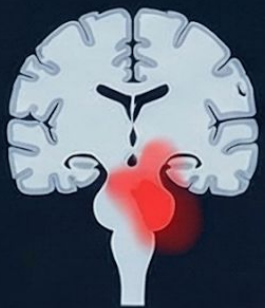
GOOD ACTIVATION (10-15%)
DEFAULT MODE NETWORK



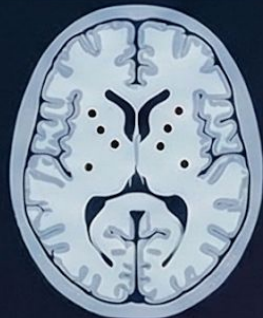PARIETO-OCCIPITAL
(VISUAL)

MILD ACTIVATION:
AUDITORY
[cite: 13, 26, 27]

CONVENTIONAL MRI FINDINGS



Subacute Brainstem Hematoma



Old Gangliobasal/Thalamic Microhemorrhages

BOLD ANALYSIS SUMMARY [cite: 10]

- 36 Components Analyzed [cite: 11]
- Mostly Mild Activations [cite: 11]
- Good: Default, Visual [cite: 12]
- Mild: Auditory [cite: 13]
- Absent: Language, Motor [cite: 14]
- Significant Artifacts/Noise [cite: 9]

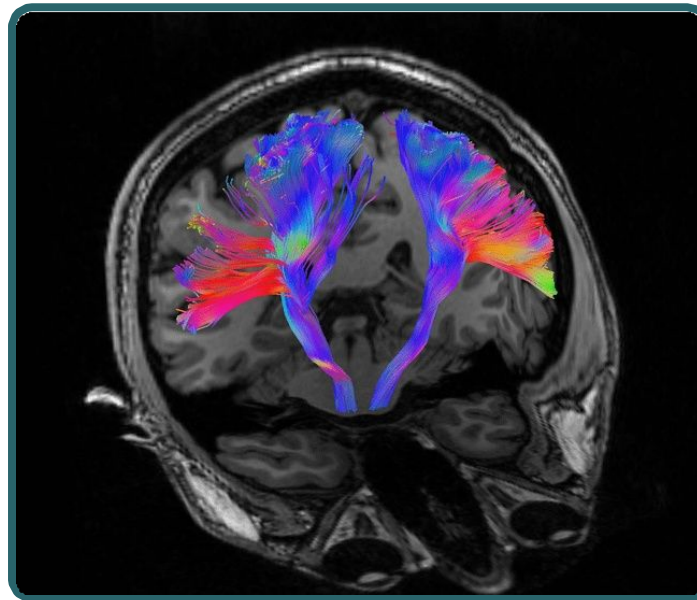


DEEP LEARNING IN TRACTOGRAPHY

NN-U-Net for CST Segmentation

The **NN-U-Net model** is used to automatically segment corticospinal tracts (CST) directly from diagnostic CT scans, enabling detailed analysis.

This deep learning technique offers a **powerful and non-invasive way** to visualize critical neural pathways.




Explore how **deep learning models** analyze CT scans for tractography, providing key insights for predicting patient motor outcomes.

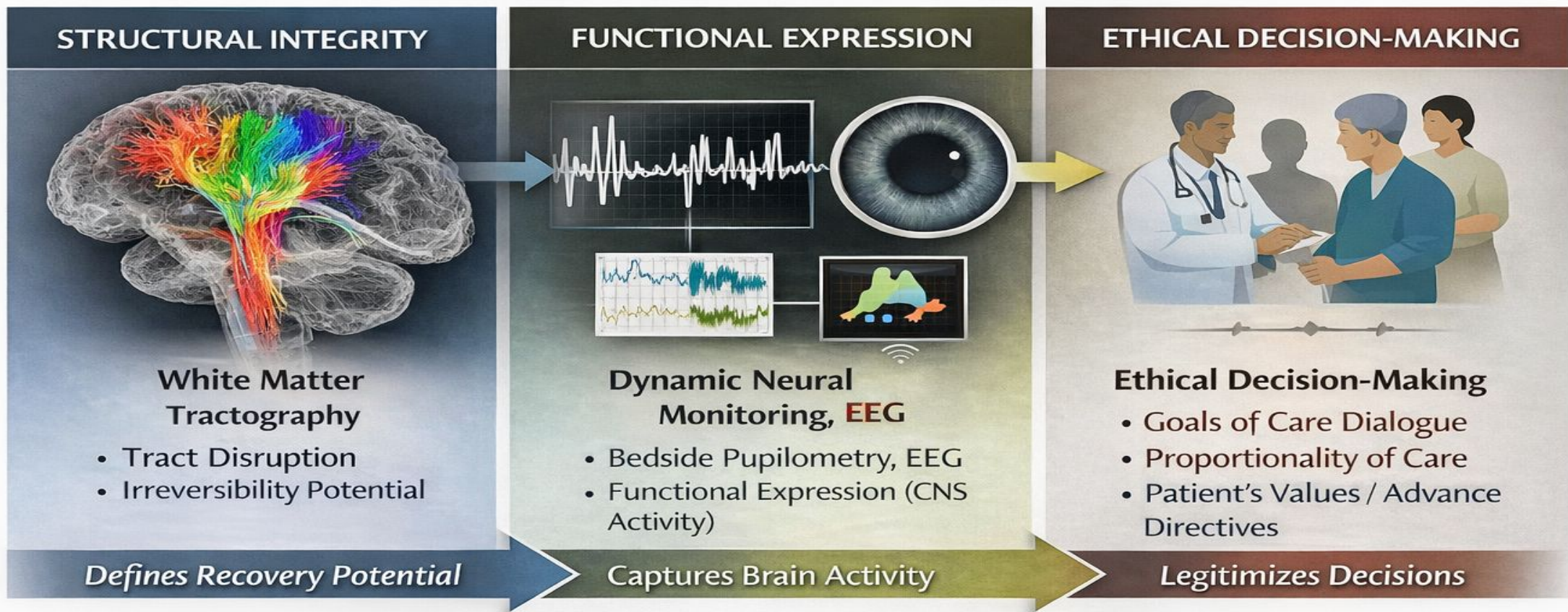
Prognostic Value of CST Integrity

Metrics derived from segmentations, which quantify **CST integrity**, have been shown to be significant predictors of motor function recovery.

This approach provides clinicians with **valuable prognostic information** early in the patient's diagnostic journey.



From Structure to Ethics: A Unified Framework for Poor Outcome Prognostication After Severe Brain Injury




**Stable Prognostic Insight
Supports Proportional Goals of Care**

- Irreversibility
- Proportionality
- Respect for Autonomy
- Family Decision-Making

Integrating Structural, Functional, and Ethical Data for Informed Prognostication and Shared Decision-Making ^(3F)



Thank you!



American Society of Neuroimaging - 49th Annual Meeting