



Synapti^{cc}ure

Tele-Imaging and Remote Reading

Neuroimaging expertise in a distributed care model

Eric Anderson, MD, PhD, MBA, FAAN
American Society of Neuroimaging • 2026

Why This Matters Now



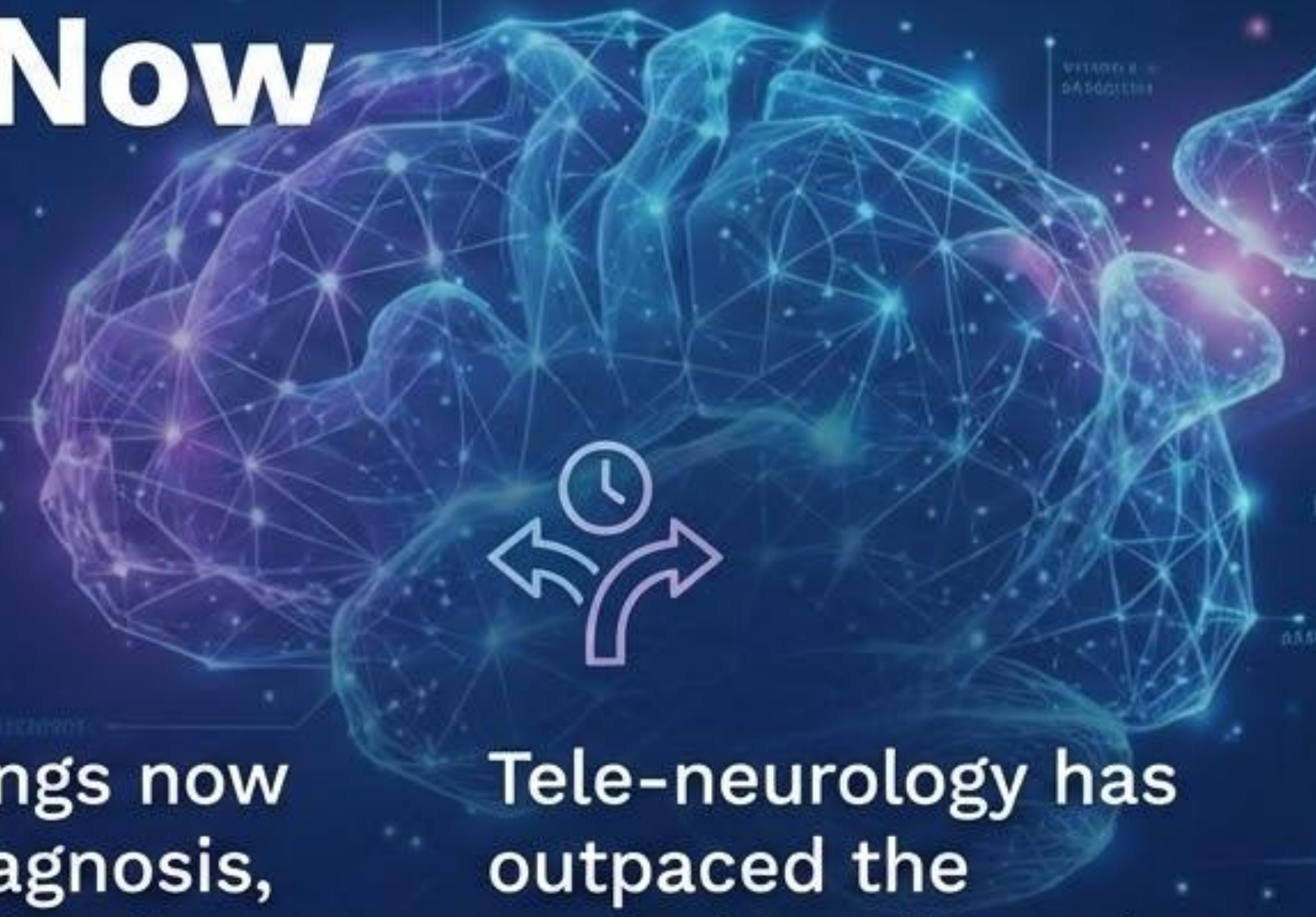Neuroimaging is no longer ancillary to neurologic care



Imaging findings now determine diagnosis, eligibility, and safety



Tele-neurology has outpaced the evolution of imaging interpretation models



The Increasing Demand for Neuroimaging

Synapticure



Aging population
with rising
prevalence of
neurologic disease





Expanded use of
MRI, CT, PET
across stroke,
dementia, MS,
epilepsy



Expectation of
greater precision
and longitudinal
comparability

The most accessible provider of neurodegenerative disease care, serving patients and caregivers in all 50 states

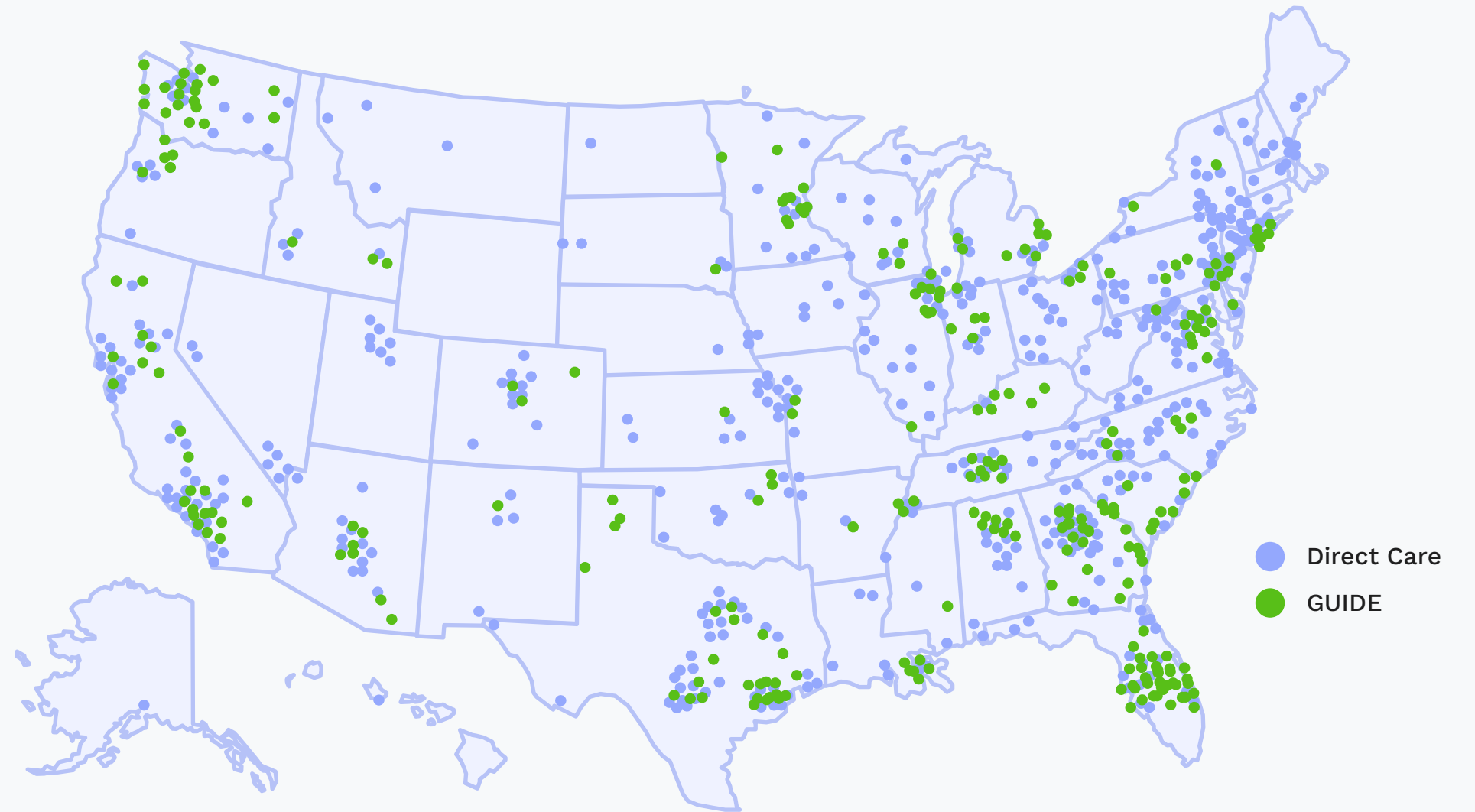- ▶ Medical practice with **50+ full-time and contracted providers**

 <p>Cognitive Alzheimer's & Related Dementias</p>	 <p>Movement Parkinson's, Huntington's</p>	 <p>Neuromuscular ALS, PLS</p>	 <p>Neuroimmune MS & others (late 2025)</p>
---	--	---	---

- ▶ In **Medicare in all 50 states** and contracted with **>50 national and regional payers** across MA, Commercial and Medicaid

- ▶ Strategic partnerships with leading **health systems, ACOs, and payers** including shared risk, and through the **CMS Dementia GUIDE program**

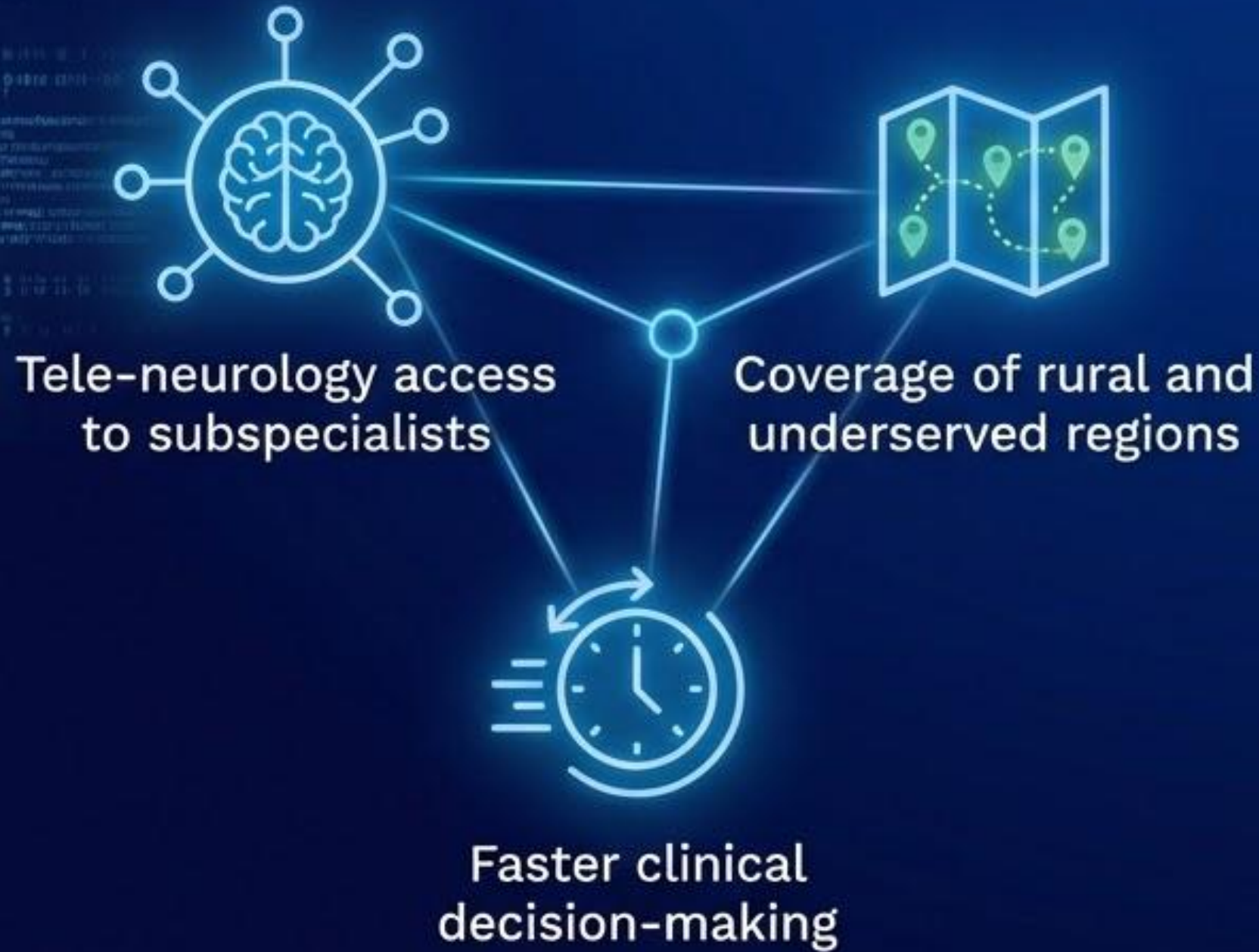
- ▶ Engaging **>10,000 patients across conditions**
 - **30%** in the most disadvantaged communities by ADI
 - **30%** non-white, **47%** household income < US median



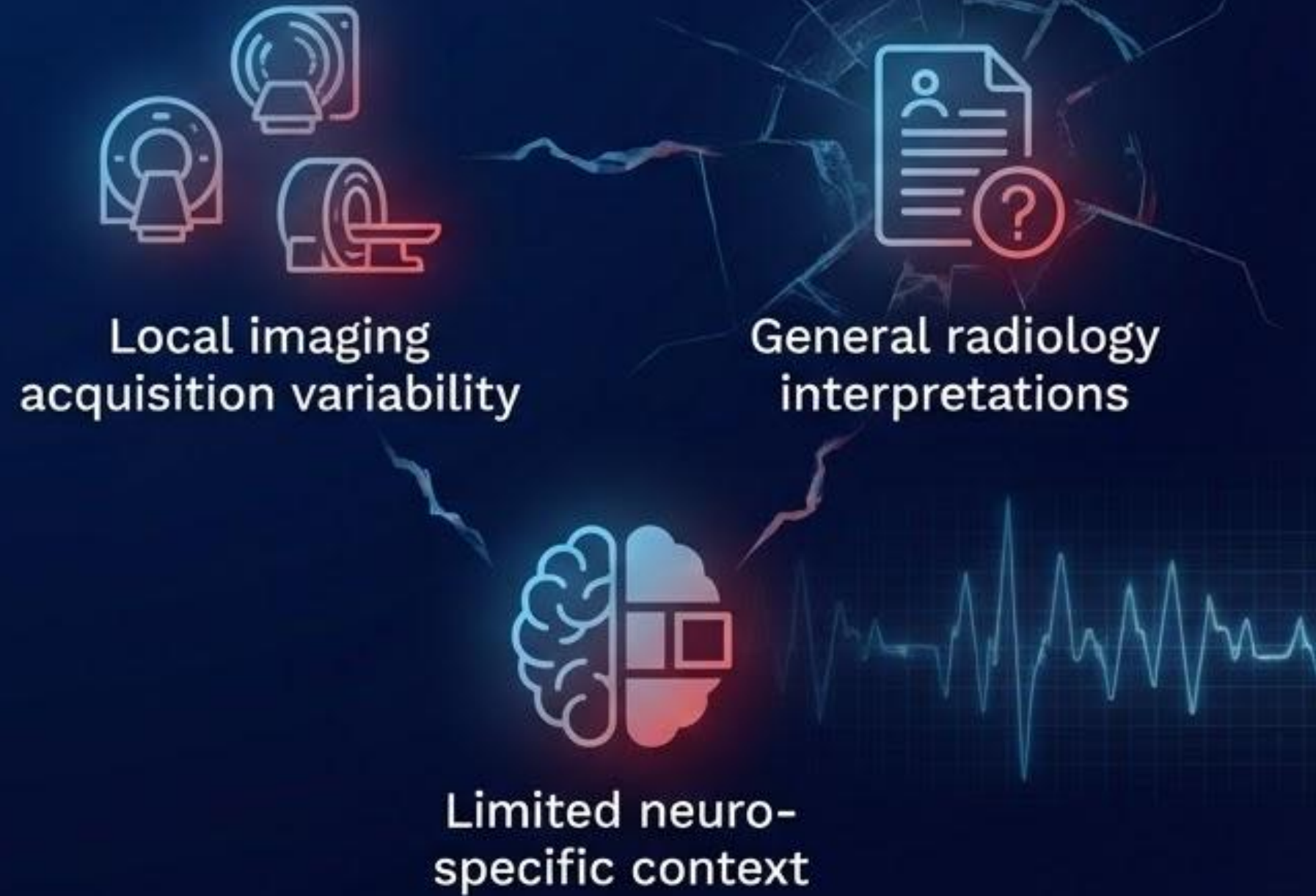Other conditions include: Progressive Bulbar Palsy (PBP), Atypical PD/PD+, Progressive Supranuclear Palsy (PSP), Multiple System Atrophy (MSA), Corticobasal Degeneration (CBD), Mild Cognitive Impairment (MCI), Frontotemporal Dementia (FTD), Lewy-body Dementia (LBD), Vascular Dementia

Reality in Hard-to-Reach Areas

What We Solved



What We Did Not Solve



Growth of Subspecialty Teleneurology



Rapid expansion of telestroke & cognitive neurology programs



Rising expectations for consistency across sites



Mismatch between subspecialty care & imaging interpretation

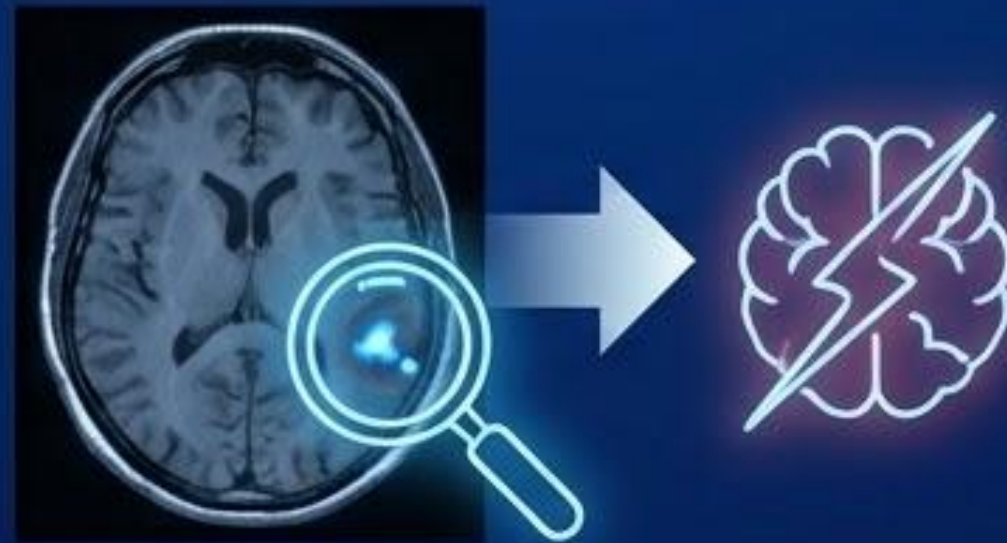The Neuroimaging Expertise Gap

Community Radiology (Breadth > Depth)



Community radiology optimized for breadth, not neurologic depth

Subtle Findings, Outsized Impact



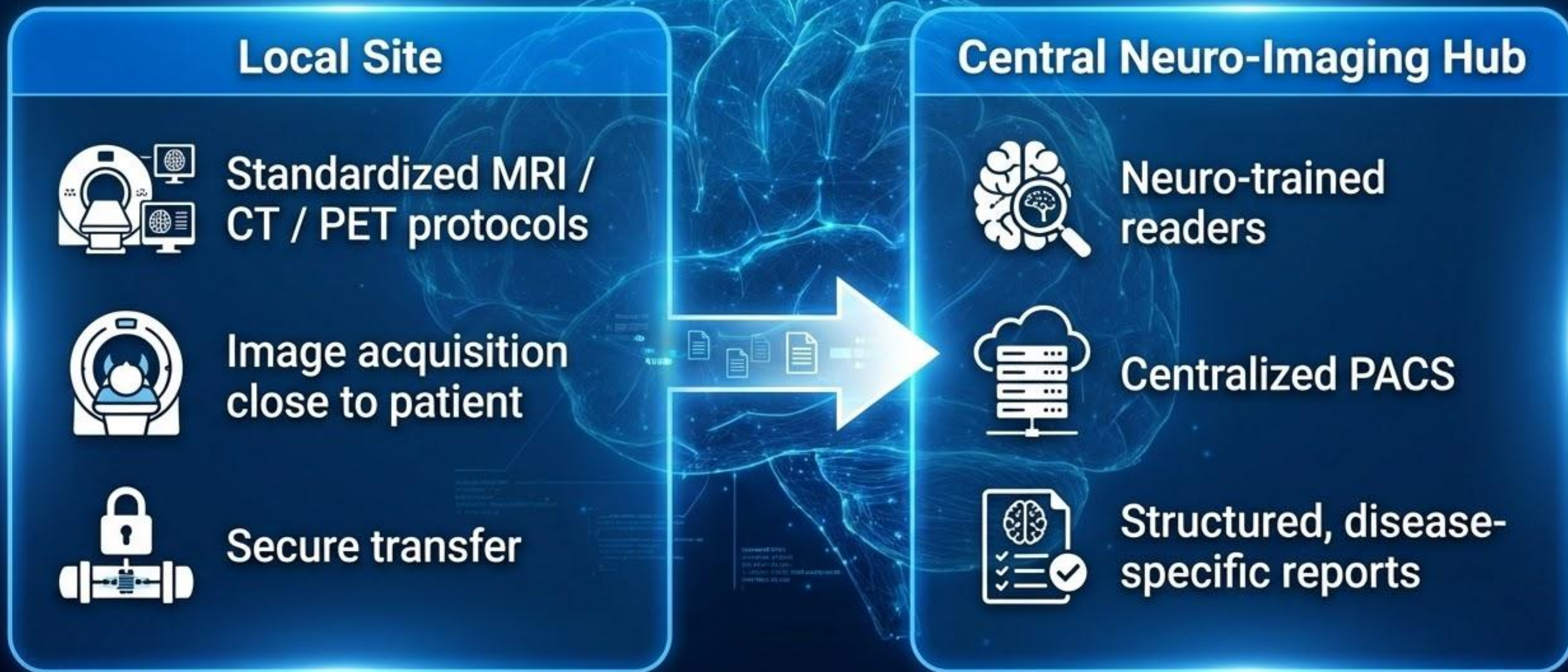
Subtle findings often have outsized clinical implications

Informal Over-Reads



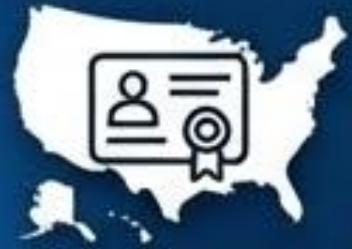Neurologists routinely perform informal over-reads

Tele-Imaging Workstream



Operational Requirements

Key Operational Pillars



**Multi-state licensure
and credentialing**



**PACS interoperability
and cybersecurity**



**Quality assurance
and peer review**



**Defined turnaround
time standards**

Peer to peer consultation exemption

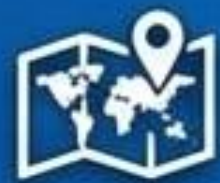

**Consulting Physician
(Out-of-State)**



**Treating Physician & Patient
(In-State)**

Allows a physician not licensed in the state in which the patient is located to consult with a physician who is licensed in the state in which the patient is located and is treating that patient.



Determined on a State by State basis

Billing and Reimbursement



Most imaging centers
retain global billing



Neuro over-reads frequently
uncompensated



Emerging models involve
secondary reads

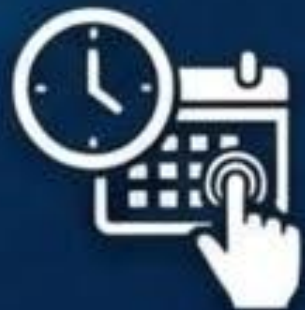Barriers to Adoption



Credentialing and legal complexity

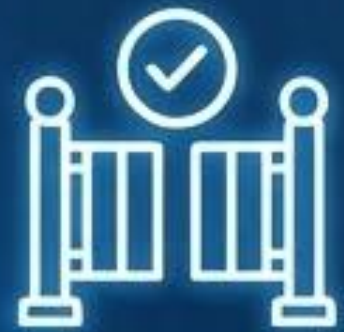

Workflow disruption and cultural resistance



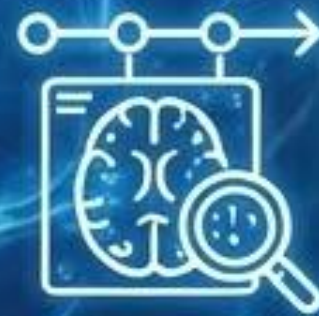Potential for on demand scheduling through a partner organization

New Therapeutics: Imaging as Gatekeeper



Baseline Eligibility

- Microhemorrhage burden
- Superficial siderosis
- White matter disease thresholds



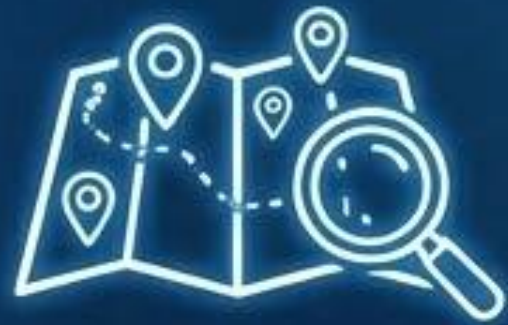Longitudinal Safety Monitoring

- ARIA-E and ARIA-H detection
- Subtle interval change
- Consistency across scanners and sites

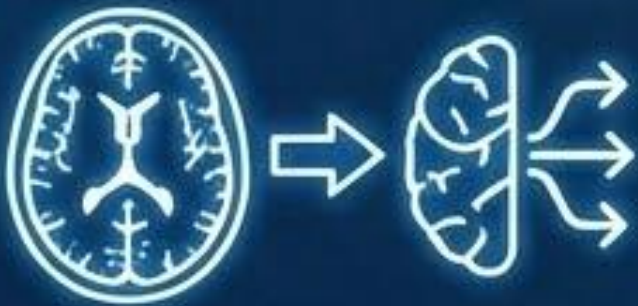
ASN Workforce Implications



Neuroimaging demand growing faster than subspecialty workforce

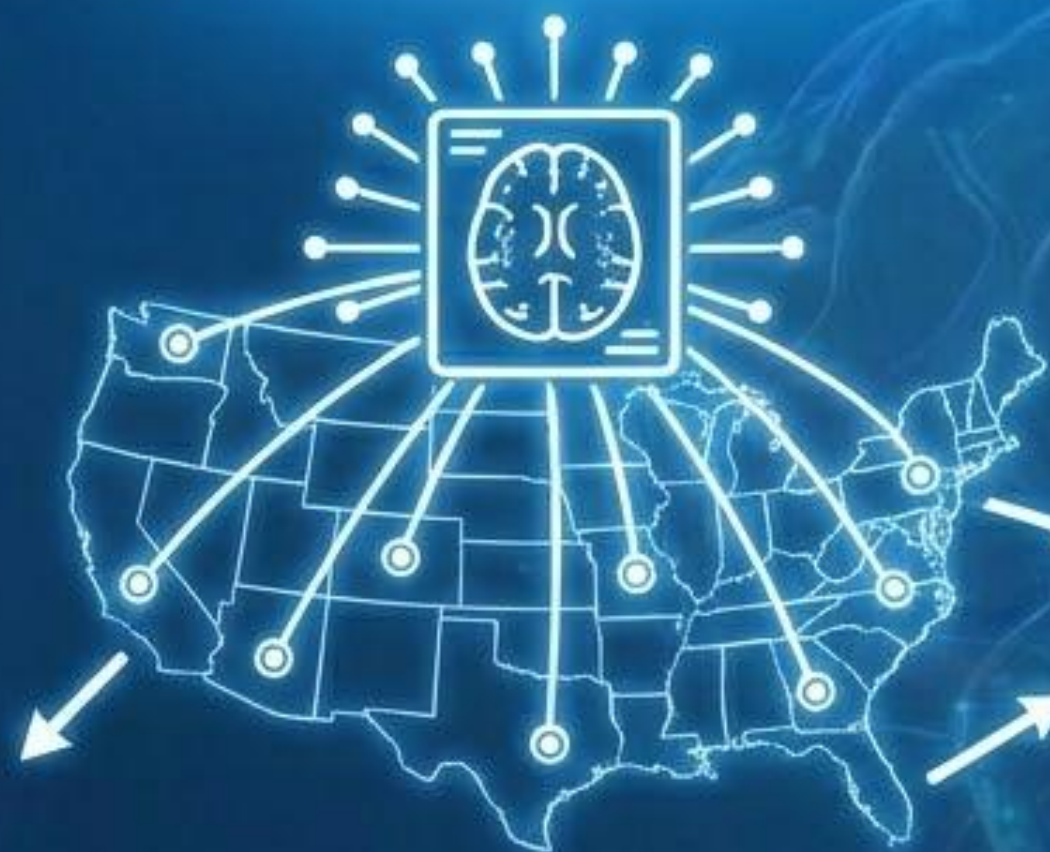

Persistent geographic maldistribution



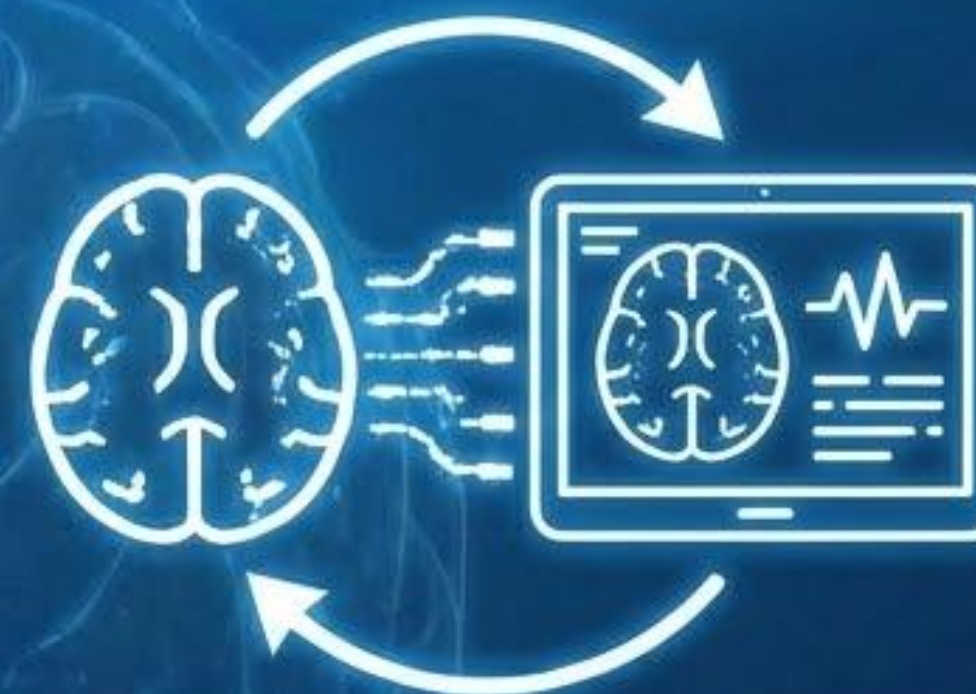
Rising reliance on general radiology for complex neurologic decisions

Future Directions



National Scale

Scale neuroimaging expertise nationally



Platform Integration

Integration of imaging into telemedicine platforms

A man and two children are posing in front of a hockey net. The man is wearing a white Easton hockey helmet and a black long-sleeved shirt. The girl on the left is wearing a white t-shirt and holding a hockey stick. The boy on the right is wearing glasses, a black Adidas hoodie, and holding a hockey stick. The background shows a white hockey net and a blue shelf with toys.

Synapti^{•••}cure

Thank You

Eric Anderson, MD, PhD, MBA, FAAN

