

# WELCOME TO THE 32<sup>nd</sup> ANNUAL MEETING OF THE AMERICAN SOCIETY OF NEUROIMAGING

January 22-25, 2009  
Hilton Walt Disney  
Orlando, FL

## ASN Mission Statement

The American Society of Neuroimaging (ASN) is an international, professional organization representing neurologists, neurosurgeons, neuroradiologists, and other neuroscientists who are dedicated to the advancement of any technique used to image the nervous system. The ASN supports the right of qualified physicians to utilize neuroimaging modalities for the evaluation and management of their patients, and the rights of patients with neurological disorders to have access to appropriate neuroimaging modalities and to physicians qualified in their use and interpretation.

The goal of the ASN is to promote the highest standards of neuroimaging in clinical practice, thereby improving the quality of medical care for patients with diseases of the nervous system. This goal is accomplished through:

- Presenting scientific and educational programs at an annual meeting and through the promotion of fellowships, preceptorships, tutorials and seminars related to neuroimaging;
- Publishing a scientific journal;
- Formulating and promoting high standards of practice and setting training guidelines;
- Evaluation of physician competency through examinations.

Emphasis is placed on the correlation between clinical information and neuroimaging data to provide the cost effective and efficient use of imaging modalities for the diagnosis and evaluation of diseases of the nervous system.

The ASN will continue to develop training and practice guidelines related to neuroimaging for:  
1) physicians in practice who currently use neuroimaging; 2) physicians in residency or fellowship training; 3) physicians in practice who wish to use neuroimaging; and 4) healthcare entities responsible for defining or allocating professional privileges and credentialing to individual physicians.

## Table of Contents

Board & Committee Members	Page 2
Program at a Glance	Page 3
Events	Page 4
2009 Course Directors and Faculty	Pages 5
Meeting Program	Pages 6-13
Presidential Address & Awards Luncheon Agenda	Page 14
1/19/2008 Minutes	Pages 15-16
Faculty Disclosures	Pages 17-18
Sponsorship/Acknowledgements	Page 19
Exhibit Diagram	Page 20
Exhibit Listings	Pages 21-22
2009 Awards	Pages 23
Program Abstracts	Pages 24-34



# ASN Board & Committee Leaders

## **EXECUTIVE COMMITTEE**

### **PRESIDENT**

Camilo Gomez, MD

### **VICE PRESIDENT**

Lawrence Wechsler, MD

### **SECRETARY**

Laszlo Mechtler, MD

### **TREASURER**

Edward Feldmann, MD

### **IMMEDIATE PAST PRESIDENT**

Rohit Bakshi, MD, FAAN

## **BOARD OF DIRECTORS**

Reeta Achari, MD

Neeraj Dubey, MD

Edward Feldmann, MD

Geoffrey Hartwig, MD

Francis Hussey, Jr., MD

David Liebeskind, MD

Bret Lindsay, MD

Marc Malkoff, MD

Mircea Morariu, MD

Adnan Qureshi, MD

Michael Sloan, MD

Earl Zimmerman, MD

## **Editor-in-Chief - JON**

Joseph Masdeu, MD, PhD

## **BOARD ADVISORS**

Andrei Alexandrov, MD, RVT

Jack Greenberg, MD

Francis Kittredge, MD

Walter Koroshetz, MD (Federal Liaison)

Joseph Masdeu, MD, PhD

Leon Prockop, MD

Charles Tegeler, MD

## **COMMITTEE CHAIRS**

### **PROGRAM COMMITTEE**

Lawrence Wechsler, MD

### **CERTIFICATION COMMITTEE**

Joseph Masdeu, MD, PhD

### **CORPORATE RELATIONS**

Scott Burgin, MD

### **NEUROSONOLOGY EXAMINATION COMMITTEE**

Andrei Alexandrov, MD, RVT

### **MEMBERSHIP COMMITTEE**

Reeta Achari, MD

### **NOMINATING COMMITTEE**

Camilo Gomez, MD

## **JOURNAL OF NEUROIMAGING OVERSIGHT COMMITTEE**

Laszlo Mechtler, MD

## **PRACTICE GUIDELINES COMMITTEE**

Lawrence Wechsler, MD

## **PRACTICE ISSUES COMMITTEE**

Francis Hussey, Jr., MD

## **MCKINNEY AWARD COMMITTEE**

Jesse Weinberger, MD

## **OLDENDORF AWARD COMMITTEE**

Ruben Kuzniecky, MD

## **QURESHI AWARD COMMITTEE**

Lawrence Wechsler, MD

## **AMERICAN SOCIETY OF NEUROIMAGING EDUCATION FOUNDATION EXECUTIVE OFFICERS/BOARD OF DIRECTORS:**

### **PRESIDENT**

Rohit Bakshi, MD, FAAN

### **VICE PRESIDENT**

John Chawluk, MD

### **TREASURER**

Joseph Masdeu, MD, PhD

### **MEMBERS**

Leon Prockop, MD

Lawrence Wechsler, MD

## **Many thanks to the ASN Program Committee for their efforts in developing this year's program:**

Chair, Lawrence Wechsler, MD

Camilo Gomez, MD

Rohit Bakshi, MD, FAAN

Reeta Achari, MD

Andrei Alexandrov, MD, RVT

Robert Bermel, MD

W. Scott Burgin, MD

John Chawluk, MD

Neeraj Dubey, MD

Dara Jamieson, MD

David Liebeskind, MD

Bret Lindsay, MD

Marc Malkoff, MD

Laszlo Mechtler, MD

Mircea Morariu, MD

Leon Prockop, MD

Adnan Qureshi, MD

Alexander Razumovsky, PhD

Michael Sloan, MD

Charles Tegeler, MD

# Program at a Glance

## THURSDAY, JANUARY 22, 2009

8:00 am – 5:00 pm	ASN Committee and Board Meetings	
3:00 – 7:00 pm	Registration Opens	
5:00 – 7:00 pm	Welcome/Poster Stand-by Reception	North Ballroom
7:00 – 9:00 pm	Interventional Cases Symposium	Center Ballroom

## FRIDAY, JANUARY 23, 2009

6:30 am – 5:00 pm	Registration	
7:00 am – 8:30 am	Breakfast Seminar: MRI Physics	Center Ballroom
7:00 am – 8:30 am	Breakfast Seminar: Ultrasound Physics	South Ballroom
8:30 am – 4:00 pm	Exhibits and Posters	North Ballroom
8:30 am – 9:00 am	BREAK	
9:00 am – 1:00 pm	MRI Course (Part I)	Center Ballroom
9:00 am – 1:00 pm	Neurosonology Course (Part I)	South Ballroom
10:30 am – 10:45 am	BREAK	
1:00am – 2:00 pm	LUNCH – Exhibit Area	North Ballroom
2:00 am – 5:00 pm	Functional Neuroimaging Symposium	South Ballroom
3:30 am – 3:45 pm	BREAK	
5:00 am – 6:30 pm	Networking Reception	Poolside
7:00 am – 10:00 pm	MRI Hands-On Workshop	Center Ballroom
7:00 am – 10:00 pm	Neurosonology Hands-On Workshop	North Ballroom

## SATURDAY, JANUARY 24, 2009

7:00 am – 4:00 pm	Registration	
7:00 am – 8:30 am	Breakfast Seminar: Ultrasound of Peripheral Nerve and Muscle: How Can I Use it to Help My Patients?	South Ballroom
7:00 am – 8:30 am	Breakfast Seminar: Perfusion Imaging	Center Ballroom
8:30 am – 9:00 am	BREAK	
9:00 am – 6:00 pm	MRI Course (Part II)	Center Ballroom
9:00 am – 6:00 pm	Neurosonology Course (Part II)	South Ballroom
10:45 am – 11:00 am	BREAK	
1:15 am – 2:45 pm	Presidential Address and Awards Luncheon	Palm IV Meeting Room
6:00 am – 8:00 pm	Networking Reception	Poolside

## SUNDAY, JANUARY 25, 2009

7:00 am– 11:10 am	Registration	
6:30 am– 8:30 am	Breakfast Seminar: The Politics of Neuroimaging: Advocacy for Training, Certification and Reimbursement in 2009	Center Ballroom
8:30 am – 9:00 am	BREAK	
9:00 am – 11:30 pm	Integrated Neuroimaging Symposium	South Ballroom
9:30 am – 3:30 pm	Neurosonology Examination (offsite)	

**Speaker Ready Room – Rose**

## Events

Thursday, January 22, 2009

**Welcome Reception**

5:00 pm - 7:00 pm

North Ballroom

Please join us for the Welcome and Poster Stand-By Reception. The Reception is complimentary for all registered attendees; guests are welcome with a \$50.00 pre-registration fee. Please visit the Registration Desk to register your guest prior to the reception.

Friday, January 23, 2009

**Networking Reception**

5:00 pm - 6:30 pm

Poolside

Please join us for cocktails and the opportunity to meet or re-connect with colleagues. All registered guests are invited to attend this complimentary function.

Saturday, January 24, 2009

**Presidential Address & Awards Luncheon**

1:15 pm - 2:45 pm

Palm IV Meeting Room

Please join us for the annual Presidential Address and Awards Luncheon, complimentary to all registered attendees. Important issues in the field of neuroimaging and ASN's position in creating change will be addressed. The Luncheon will also include presentation of the 2009 awards.

**Networking Reception**

6:00 pm - 8:00 pm

Poolside

Please join us for cocktails and the opportunity to meet or re-connect with colleagues. All registered guests are invited to attend this complimentary function.

## 2009 Course Directors and Faculty

**Reeta Achari, MD**  
Houston, Texas

**Andrei Alexandrov, MD, RVT**  
Fountain Hills, AZ

**John B. Chawluk, MD**  
Pottsville, Pennsylvania

**Patrick Capone, MD, PhD**  
Winchester Neurological  
Consultants, Inc.  
Winchester, Virginia

**Neeraj Dubey, MD**  
Dubois, Pennsylvania

**Ed Eichhorn**  
President  
Medilink Consulting Group LLC  
Dumont, New Jersey

**Zsolt Garami, MD**  
University of Texas-Houston  
Department of Neurology  
Houston, Texas

**Camilo Gomez, MD**  
Alabama Neurological Institute  
Birmingham, Alabama

**Geoffrey Hartwig, MD**  
Hattiesburg Clinic  
Hattiesburg, Mississippi

**Michael Hutchinson, MD, PhD**  
New York University School of  
Medicine  
New York, New York

**Tudor Jovin, MD**  
University of Pittsburgh Medical  
Center  
Pittsburgh, Pennsylvania

**Jawad F. Kirmani, MD**  
Director, Stroke Center  
Assistant Professor, Neurology and  
Neurosciences  
Newark, New Jersey

**Ruben Kuzniecky, MD**  
NYU - Epilepsy Center  
New York, New York

**David S. Liebeskind, MD**  
Associate Neurology Director, UCLA  
Stroke Center & Neurology Director,  
Stroke Imaging Program  
Los Angeles, California

**Bret Lindsay, MD**  
Glacier Neurological  
Kalispell, Montana

**Eric Lindzen, MD, PhD**  
SUNY Buffalo, Department of Neurology  
Buffalo, New York

**Joseph Masdeu, MD, PhD**  
University of Navarre Medical School  
Pamplona, Spain

**Laszlo Mechtler, MD**  
Associate Professor Neurology  
SUNY at Buffalo  
Buffalo, New York

**Mircea Morariu, MD**  
Florida Neurologic Center PA  
Delray Beach, Florida

**Michael Moseley, PhD**  
Professor of Radiology  
Stanford University  
Stanford, California

**Erasmus Passaro, MD**  
Bayfront Medical Center  
St. Petersburg, Florida

**Joseph Polak, MD, MPH**  
Professor of Radiology  
Tufts University School of Medicine  
Director of Cardiovascular Imaging  
Tufts-New England Medical Center  
Boston, Massachusetts

**William Preston, MD, FAAN**  
Associate Clinical Professor of Neurology  
UCI School of Medicine  
Laguna Hills, California

**Adnan Qureshi, MD**  
Executive Director, Stroke Center  
Associate Head, Department of Neurology  
Professor of Neurology, Neurosurgery,  
and Radiology  
University of Minnesota  
Minneapolis, Minnesota

**Alexander Razumovsky, PhD**  
Director, Critical Care/Neurovascular  
Division  
Sentient Medical Systems, Inc.  
Cockeysville, Maryland

**Alice Robinson, MD**  
UAB Comprehensive Stroke Center  
Birmingham, Alabama

**Brian Ross, MD**  
Clinical MR Spectroscopy Unit  
Huntington Medical Research Institute  
Pasadena, California

**Steven Shook, MD**  
Neurological Institute  
Cleveland Clinic  
Cleveland, Ohio

**Michael Sloan, MD**  
Carolinas Medical Center  
Division of Neurology  
Charlotte, North Carolina

**Gabriella Szatmary, MD, PhD**  
Director, Neuro-Ophthalmology Clinic  
Department of Neurology  
Hattiesburg Clinic P.A.  
Hattiesburg, Mississippi

**Charles Tegeler, MD**  
Professor of Neurology  
Head, Section on Stroke and CVD  
Medical Director, Neurosonology  
Laboratory  
Wake Forest University School of Medicine  
Winston-Salem, North Carolina

**Osama Zaidat, MD**  
Director, Interventional Neurology;  
Associate Professor of Neurology and  
Neurosurgery  
Medical College of Wisconsin  
Milwaukee, Wisconsin

**A special thank you to all ASN Course Directors and Faculty for their  
donation of time and personal resources to the success of this meeting.**

# 2009 Program

**Thursday, January 22, 2009**

## **Interventional Cases Symposium**

7:00 – 9:00 pm

Center Ballroom

Director: Tudor G. Jovin, MD

Faculty: Camilo R. Gomez, MD, Jawad F. Kirmani, MD, Osama O. Zaidat, MD, MSc, Adnan I Qureshi, MD,

Tudor G. Jovin, MD

CME: 2 Hours

7:00 -7:12 pm	Endovascular Therapy of Acute Ischemic Stroke: Patient Selection	Tudor Jovin, MD
7:12-7:24 pm	Endovascular Treatment of Acute Ischemic Stroke: Treatment Modalities	Adnan Qureshi, MD
7:24-7:36 pm	Symptomatic Intracranial Atherosclerotic Disease: Stenting and Angioplasty	Osama Zaidat, MD MSc
7:36- 7:48 pm	Symptomatic Extracranial Vertebral Artery Stenosis: Natural History and Endovascular Treatment Options	Jawad Kirmani, MD
7:48-8.00 pm	Extracranial Carotid Artery Disease: Stenting or Endarterectomy?	Camilo R. Gomez, MD
8:00-9:00 pm	Case Presentation and Discussion	

This seminar will provide an update of the latest developments in endovascular therapy for ischemic stroke. Diseases amenable to endovascular treatment such as acute ischemic stroke due to large vessel occlusion, symptomatic extracranial vertebral artery disease, symptomatic intracranial atherosclerotic disease, carotid artery disease will be discussed. Emphasis will be placed on patient selection and the continuously evolving armamentarium of endovascular treatment modalities. Practical applications in acute stroke and chronic neurovascular disorders will be outlined. The course is designed for physicians and other health care providers interested in the diagnosis and management of ischemic cerebrovascular conditions amenable to endovascular treatment.

Upon completion of this seminar, attendees will have a good understanding of:

- 1) the spectrum of ischemic cerebrovascular diseases amenable to endovascular therapy
- 2) patient selection paradigms including those based on imaging modalities
- 3) various endovascular treatment options
- 4) alternative treatment options including medical management or open surgical approaches
- 5) complications and pitfalls of endovascular procedures pertaining to these conditions

The course is intended for those individuals interested in familiarizing themselves with endovascular therapies for ischemic stroke as well for those who are seeking to focus on specific aspects that impact clinical practice. The educational value of the material presented will be enhanced by encouraging active participation in the second part of the symposium which consists of an open discussion of presented cases.

**Friday, January 23, 2009**

**Breakfast Seminar: MRI Physics**

Center Ballroom

7:00 – 8:30 am

Director and Faculty: Michael E. Moseley, PhD

CME: 1.5 Hours

7:00 – 7:45 am	Basic MRI Physics	Michael E. Moseley, PhD
7:45 – 8:30 am	Beyond the Basics of MR Neuroimaging	Michael E. Moseley, PhD

This seminar will familiarize the attendee with basic MR physics principles and concepts relating to simple concepts of MR physics and introduce new and evolving MR technologies in neuroimaging to the practicing neurologist. Topics will include simple to advanced MRI principles and practices, the rationale of MR tissue contrast, new MR techniques and evolving MR protocols. The seminar is intended for physicians interested in learning or refreshing MR physics principles and techniques.

Upon completion of this seminar, attendees will have a firm understanding of the:

- 1) basic to advanced principles involved in MR physics,
- 2) image acquisition,
- 3) tissue contrast,
- 4) new and evolving techniques now available to the practicing neuroimaging neurologist.

This course is intended for physicians interested in learning or refreshing MR physics principles and techniques.

**Breakfast Seminar: Ultrasound Physics**

South Ballroom

7:00 – 8:30 am

Director and Faculty: Andrei Alexandrov, MD, RVT

CME: 1.5 Hours

This seminar is being offered to review ultrasound physics and fluid dynamics, demonstrate typical imaging artifacts and waveforms that interpreting physicians and sonographers need to identify and correct and to interact with the audience and answer questions about these typical findings. Course faculty will discuss applied principles of ultrasound physics and fluid dynamics using a set of approximately 50 typical images/waveforms. Discussion format includes brief case/symptom presentation and an ultrasound image. Faculty will ask the audience to interpret the image, and engage in discussion of differential diagnosis and common pitfalls that are linked to ultrasound physics and fluid dynamics.

Upon completion of this activity, participants will be able to:

- 1) Review most common ultrasound imaging artifacts and spectral waveforms.
- 2) Learn key principles of applied ultrasound physics and fluid dynamics that are responsible for these findings.
- 3) Learn how to differentiate, optimize and interpret typical ultrasound imaging artifacts and spectral waveforms.

## **MRI Course Part I**

Center Ballroom

9:00 am – 1:00 pm

Directors: Bret Lindsay, MD and Neeraj Dubey, MD

Faculty: Joseph Masdeu, MD, Laszlo Mechtler, MD, Eric Lindzen, MD

CME: 3.75 Hours

9:00 -10:00 am	Ischemic Infarction	Bret Lindsay, MD
10:00 -11:00 am	Dementia	Joseph Masdeu, MD
11:00 -11:10 am		Break
11:10 am -12:00 pm	Brain Neoplasm	Laszlo Mechtler, MD
12:00 -1:00 pm	Hemorrhage	Eric Lindzen, MD

Course Objectives: Examine and understand the application of MRI in various disease processes involving the human brain and spine. Review and understand typical MR imaging findings in ischemic infarction, dementia, brain neoplasm and brain hemorrhage.

## **Neurosonology Part I**

South Ballroom

9:00 am – 1:00 pm

Director: Alexander Razumovsky, PhD

Faculty: J. Polak, MD, MPH, Andrei Alexandrov, MD, RVT

CME: 3.75 Hours

9:00 – 9:45 am	Carotid Ultrasound: Physics & Technique	J. Polak, MD, MPH
9:45 – 10:45 am	Carotid Ultrasound: Interpretation & Clinical Application	J. Polak, MD, MPH
10:30 – 10:45 am	Coffee Break	
10:45 – 11:45 am	Transcranial Doppler Ultrasound: Physics & Technique	Andrei Alexandrov, MD, RVT
11:45 am – 12:45 pm	Transcranial Doppler Ultrasound: Interpretation & Clinical Application	Alexander Razumovsky, PhD

This course is for individuals interested in performing and interpreting neurosonology (carotid and transcranial Doppler (TCD) ultrasound) studies. The faculty will discuss carotid and ultrasound physics and technique, interpretation and clinical application of both techniques. Ample time will be left for question and discussion. Upon completion of this course, participants will be able to identify the physics, technique, interpretation and clinical applications of the carotid and TCD ultrasound. The course material is designed for participants seeking basic knowledge of neurosonology.

## **Functional Neuroimaging Symposium**

South Ballroom

2:00 – 5:00 pm

Director: Joseph C. Masdeu, MD, PhD

Faculty: Joseph C. Masdeu, MD, PhD, David S. Liebeskind, MD, Ruben Kuzniecky, MD, PhD, Brian Ross, PhD

CME: 3 Hours

2:00 – 2:05 pm	Introduction	Joseph C. Masdeu, MD, PhD
2:05 - 2:45 pm	Functional imaging of stroke	David S Liebeskind, MD
2:45 – 3:30 pm	Functional imaging of epilepsy	Ruben Kuzniecky, MD, PhD
3:30 – 3:45 pm	Coffee Break	
3:45 – 4:15 pm	Functional imaging of dementia	Joseph C. Masdeu, MD, PhD
4:15 – 5:00 pm	MR Spectroscopy	Brian D. Ross, PhD

The faculty will review the applications of functional neuroimaging to stroke, epilepsy and dementia, as well as the applicability of magnetic resonance spectroscopy (MRS) to the diagnosis and follow-up of neurological disorders. Functional neuroimaging techniques include CT perfusion, functional MRI, diffusion vector imaging, MRS, perfusion and diffusion MR, SPECT and PET, among others.

Upon completion of the course, physicians will be able to:

- 1) list the functional neuroimaging tools most frequently used in neurological practice and clinical research.
- 2) indicate the most frequent patterns in stroke, epilepsy and dementia.
- 3) discuss the indications for the performance of functional neuroimaging procedures.

This course is intended for neurologists, neurosurgeons, radiologists, fellows and residents interested in neuroimaging.

## **MRI Hands-On Workshop**

Center Ballroom

7:00-10:00 pm

Director: Geoffrey Hartwig, MD

CME: 3 Hours

Workshop participants will rotate among reading stations supervised by the course faculty. After a brief review of the expert's approach to interpreting brain and spine MRI studies, the students will read a selection of scans brought in by the faculty. Course participants will be expected to present mock dictations of the MRI studies and will be critiqued by their peers and professors. Controversial cases will be discussed among the entire group of participating faculty and students. This workshop is designed for participants with some practical experience in interpreting brain and spine MRI scans. Those with less experience may wish to participate, although they may find the workshop to be exceptionally challenging.

Upon completion of the workshop attendees will:

- 1) Have been exposed to a representative cross-section of neurological MRI studies encountered by MRI neuroimagers in a typical work environment;
- 2) Have observed the experienced MRI expert's approach to scan interpretation;
- 3) Have acquired personal experience interpreting neurological MRI studies; and
- 4) Have been supervised and directed in improving their reading skills at their own workplaces.

## **Neurosonology Hands-On Workshop**

North Ballroom

7:00-10:00 pm

Director: Andrei Alexandrov, MD, RVT

Faculty: Zsolt Garami, MD, Alice Robinson, MD, Alexander Razumovsky, PhD, Charles Tegeler, MD, Michael Sloan, MD, Joseph Polak, MD, MPH

CME: 3 Hours

This workshop will provide structured hands-on and question and answer sessions in carotid/vertebral duplex and specific transcranial Doppler techniques complete testing, emboli detection, right-to-left shunt detection and assessment of vasomotor reactivity. Both the beginner and experienced users are encouraged to attend. The workshop will also provide an opportunity to try the latest equipment, to meet experts and to discuss various aspects of neurosonology in small groups. The workshop is designed to meet the need for basic and advanced knowledge of insonation techniques, technological advances, and practical aspects of cerebrovascular testing.

### **Objectives:**

Upon completion the participants will review complete scanning protocols for diagnostic carotid/vertebral duplex and TCD examinations, vasomotor reactivity, emboli detection, right-to-left shunt testing, and monitoring procedures (thrombolysis, head-turning, peri-operative testing), and IMT measurements. The participants will review equipment and expertise requirements in performing selected tasks with faculty using hands-on, instructional video or real time case recordings.

## **Saturday, January 24, 2009**

### **Breakfast Seminar: Ultrasound of Peripheral Nerve and Muscle: How Can I Use it to Help My Patients?**

South Ballroom

7:00 – 8:30 am

Director and Faculty: Steven Shook, MD

CME: 1.5 Hours

Faculty will review the practical aspects of utilizing high-frequency ultrasound to evaluate peripheral nerve and muscle in clinical practice. Normal ultrasonographic anatomy and findings in various disease states will be discussed. Emphasis will be placed on diagnosis of focal peripheral neuropathies, including entrapment neuropathies (e.g. carpal tunnel syndrome, and ulnar neuropathy at the elbow), nerve trauma and nerve tumors.

Upon completion of this course, participants will:

- 1) Understand benefits and limitations of neuromuscular ultrasound (NM US).
- 2) Appreciate how NM US compliments MRI and EMG in the diagnosis of disorders of the peripheral nervous system.
- 3) Identify specific indications for which NM US is proven useful in clinical practice, based on the most up-to-date literature.

This course is intended for neurologists, physiatrists, radiologists, fellows and residents interested in US imaging of disorders of the peripheral nervous system.

## **Breakfast Seminar: Perfusion Imaging**

7:00 – 8:30 AM

Center Ballroom

Director: David S Liebeskind, MD

Faculty: David S Liebeskind, MD and Tudor Jovin, MD

CME: 1.5 Hours

7:00 – 7:35 am	Principles and Potential of Perfusion Imaging: Realizing Cerebral Blood Flow from Hemodynamics to Permeability	David S Liebeskind, MD
7:35 – 7:45 am	Discussion	
7:45 – 8:20 am	Use of CT and MRI Perfusion from Acute to Chronic Ischemia	Tudor Jovin, MD
8:20 – 8:30 am	Discussion	

This seminar will introduce and explore the vast potential of perfusion imaging methods in current and future clinical practice scenarios ranging from stroke to neuro-oncology. The basic concepts of various perfusion modalities, including CT, MRI and angiography, will be described. The technical aspects and mathematics will be presented from the clinical perspective, exploring how these tools can be used to detail microvascular changes in the blood-brain barrier and complex hemodynamics. Practical applications in acute stroke and chronic neurovascular disorders will be outlined. The course is designed for all neuroimaging enthusiasts that encounter blood flow alterations in clinical practice.

Upon completion of this seminar, attendees will have a firm understanding of:

- 1) basic concepts involved in imaging blood flow in the brain
- 2) current and evolving perfusion imaging modalities
- 3) how the mathematics of perfusion imaging translate into specific hemodynamic measures
- 4) applications from acute stroke to prevention of hemodynamic compromise

The course is intended for those individuals interested in first learning about perfusion imaging to those focused on specific aspects that impact clinical practice. Discussion of innovative approaches to perfusion imaging will underscore the mounting enthusiasm for these neuroimaging modalities.

## **MRI Course Part II**

9:00 am – 6:00 pm

Center Ballroom

Directors: Bret Lindsay, MD, Neeraj Dubey, MD

Faculty: Bret Lindsay, MD, Neeraj Dubey, MD, John Chawluck, MD, Erasmo Passaro, MD,  
Gabriella Szatmary, MD, Eric Lindzen, MD

CME: 6.75 Hours

9:00 – 10:00 am	Headache	John Chawluck, MD
10:00 – 11:00 am	Epilepsy	Erasmo Passaro, MD
11:00 – 11:10 am	Break	
11:10 am – 12:00 pm	Vascular Malformations	Neeraj Dubey, MD
12:00 – 1:00 pm	Multiple Sclerosis	Bret Lindsay, MD

1:00 – 3:00 pm	Break	
3:00 – 4:00 pm	Visual System	Gabriella Szatmary, MD
4:00 – 5:00 pm	Degenerative Spine	TBA
5:00 – 6:00 pm	Neuroimaging Jeopardy	Eric Lindzen, MD

Course Objectives: Examine and understand the application of MRI in various disease processes involving the human brain and spine. Review and understand typical MRI findings in headache, epilepsy, vascular malformations, multiple sclerosis, visual system pathology, degenerative spine disease and interesting case studies in neuroimaging.

### **Neurosonology Part II**

South Ballroom

9: 00 am – 6:00 pm

Director: Alexander Razumovsky

Faculty: Charles Tegeler, MD, Andrei Alexandrov, MD, RVT

CME: 6.75 Hours

9:00 – 10:45 am	Neurosonology Interpretation	Charles Tegeler, MD Andrei Alexandrov, MD, RVT
10:45 - 11:00 am	Coffee Break	
11:00 am - 1:00 pm	Neurosonology Interpretation (Continued)	Charles Tegeler, MD Andrei Alexandrov, MD, RVT
1:15 – 2:45 pm	ASN Business Meeting	
3:00 – 3:45 pm	Specific TCD application for patients with stroke	Andrei Alexandrov, MD, RVT
3:45 – 4:15 pm	Specific TCD applications for patients after SAH	Alexander Razumovsky, PhD
4:15 – 4:30 pm	Coffee Break	
4:30 – 5:15 pm	Advanced Emboli Monitoring: Clinical Implications	Alexander Razumovsky, PhD
5:15 – 6:00 pm	Advanced TCD monitoring during cardiovascular and cardiothoracic surgeries	Alexander Razumovsky, PhD
6:00 – 6:15 pm	Q&A	

This course is for individuals interested in performing and interpreting advanced transcranial doppler (TCD) ultrasound) studies for specific applications, like for patients after ischemic stroke, SAH, cryptogenic stroke, application and interpretation of TCD for patients with PFO and advanced TCD monitoring during cardiovascular and cardiothoracic surgeries. The faculty will discuss TCD ultrasound technique and interpretation of different procedures. Ample time will be left for questions and discussion. Upon completion of this course, participants will be able to identify interpretation and clinical applications of abovementioned specific TCD applications. The course material is designed for participants seeking advanced knowledge of neurosonology and its clinical applications.

**Sunday, January 25, 2009**

**Breakfast Seminar: The politics of Neuroimaging: Advocacy for Training, Certification and Reimbursement in 2009**

6:30 – 8:30 am

Center Ballroom

Directors: William Preston, MD, FAAN, Michael A. Sloan, MD, MS

Faculty: Eric Lindzen, MD, Michael Hutchinson, MD, PhD, Ed Eichhorn, BE, MBA

CME: 2 Hours

As neurologists become increasingly involved with the professional practice of MRI, CT and Neurosonology, the need for a working knowledge of related political issues becomes paramount. Dynamic advocacy for neuroimaging is essential to neurology's continued success as a vital medical specialty. This course will discuss the powerful forces currently impacting neuroimaging: political trends in an era of contracting medical resources; physician specialty turf conflicts; organizations that control neuroimaging policy and education; issues of self-referral.

Upon completion of the course, physicians will:

- 1) Understand the general principles affecting neuroimaging politics and continuing education
- 2) Become familiar with the organizations responsible for neuroimaging oversight regarding appropriateness guidelines, quality control and physician reimbursement
- 3) Know the difference between self-referral and over-utilization
- 4) Apply knowledge of neuroimaging practice issues to personal professional circumstances and strategies

This seminar is a must for any ASN member interested in sharing in our organization's future, as we move forward to formulate an advocacy strategy for 2009.

**Integrated Neuroimaging Symposium**

South Ballroom

9:00 - 11:30 am

Director: Reeta Achari, MD

CME: 2.5 Hours

The course will include interactive case presentations that illustrate clinical and neuroimaging correlations of interesting or unusual neurologic conditions. Patient material will be presented incrementally, including history, examination, laboratory and neuroimaging data. This will allow sequential discussion and debate about differential diagnosis, paraclinical testing, and therapeutic decisions. Audience participation will be encouraged. The cases will emphasize the use of interventional endovascular procedures, neurosonology and MRI, including advanced MRI techniques and their correlation with clinical and laboratory investigations. The course is appropriate for a wide audience including neurologic trainees, neuroimagers, and clinical neurologists.

Upon completion of this course, attendees will:

- 1) Understand the use of a variety of neuroimaging methods, both invasive and noninvasive, in clinical neurology; and
- 2) Understand the use of advanced MRI techniques such as MR spectroscopy and diffusion weighted imaging.

# PRESIDENTIAL ADDRESS & AWARDS LUNCHEON

ASN Business Meeting

AGENDA

Saturday, January 24, 2009

1:15-2:45 pm

Palm IV

Hilton Walt Disney – Orlando, Florida

1. Call to Order
2. Approval of Minutes – January 19, 2008 Business Meeting
3. President's Report – *Camilo Gomez, MD*
  - a) Recognition of Dr. Wechsler's service as Vice President
  - b) Recognition of Dr. Mechtler's service as Secretary
  - c) Recognition of Dr. Malkoff's service as a Board Member
  - d) Recognition of Dr. Zimmerman's service as Board Member
  - e) Slate of Candidates:
    - Dara Jamieson , MD – Vice President Position
    - Marc Malkoff, MD – Secretary Position
    - Jeff Greenberg, MD – Board Position
    - Mike Hutchinson, MD – Board Position
4. Program Committee Report – *Lawrence Wechsler, MD*  
2010 Annual Meeting: San Francisco, California, January 14-17, 2010
5. Treasurer's Report – *Edward Feldman, MD*
6. Practice Issues Committee Report – *Francis Hussey, Jr., MD*
7. Journal of Neuroimaging Report – *Joseph Masdeu, MD, PhD*
8. Fellowship/Training Committee Report – *Lazlo Mechtler, MD*
9. John and Sophie Prockop Memorial Lectureship - *Leon Prockop, MD*  
Presented to: Stafford Conway, MD  
*Quantitative Magnetic Resonance Angiography of the Cerebrovasculature in Physiologic and Pathologic States*
10. Presentation of the Qureshi Award – *Adnan Qureshi, MD*  
Presented to: Jefferson Miley, MD  
*Endovascular Retrieval of a Premature Covered Stent Deployment; Technical Report.*
11. Presentation of Oldendorf Award – *Camilo Gomez, MD*  
Presented to: *Mohit Neema, MD*  
*3T MRI Relaxometry Detects T2 Prolongation in the Cerebral Normal-Appearing White Matter in Multiple Sclerosis*
12. Presentation of Trainee Travel Awards – *Camilo Gomez, MD*  
Presented to: *Rizwan Bashir, Sarah Khan, MD*
13. New Business
14. Adjourn



# AMERICAN SOCIETY OF NEUROIMAGING

**Presidential Address & Awards Luncheon  
ASN Business Meeting  
Saturday, January 19, 2008  
Westin La Paloma – Tucson, Arizona  
MINUTES**

The meeting was called to order by Dr. Camilo Gomez, President.

**On motion seconded and carried, the minutes from the January 20, 2007 meeting were approved as submitted.**

Dr. Gomez gave the President's Report in which he explained that while ASN is a viable, active and diligent organization we need to be careful not to be complacent. A strong membership and financial strength will allow the society to grow. To achieve this there must be a membership initiative that includes an appeal to residents and their program directors. ASN provides its members education, advocacy and certification. The membership can assist ASN by becoming a mentor, communicating with program directors and residents and encouraging others to become members.

Dr. Gomez thanked Dr. Jamieson, outgoing Treasurer, and Dr. Hussey, outgoing Board member, for their service and announced the slate of candidates. The candidates proposed were: Dr. Feldmann, Treasurer, and Drs. Preston and Jovin as Board members.

**On motion seconded and carried, the membership approved the appointment of Dr. Feldmann to the Executive Committee/Board of Directors as Treasurer and the appointment of Drs. Preston and Jovin as members of the Board of Directors.**

## **Program Committee Report**

Dr. Wechsler encouraged attendees to sign up to attend the Havana Nights social event Saturday night and announced the 2009 meeting will be held in Orlando, FL January 22-25. He also announced that the Board of Directors had discussed locations for the 2010 meeting and the Executive Office would be exploring sites on the West Coast.

## **Treasurer's Report**

Dr. Jamieson echoed Dr. Gomez's comments on the future of the society. The amount of dues collected remains steady and therefore, the revenue from the annual meeting becomes more important. She also pointed out that interest from investments may be declining due to the state of the financial markets. It will be important to increase revenues to ensure viability of the society.

## **Practice Issues Committee Report**

Dr. Hutchinson reported in Dr. Hussey's absence that the biggest issue at this time is the need to defend the interest of neuroimagers and that the committee and Board are considering a proposal from lobbyist Mr. Ed Eichhorn.

## **Journal of Neuroimaging Report**

Dr. Masdeu reported that submissions have greatly increased and that Blackwell has done a great job publicizing the journal. Case reports have increased threefold and investigative reports have increased as well. A new layout has been implemented that allows for increased content and has removed the previous limit on number of authors. A new section, News and Tips, has been introduced that will highlight certification, training and work opportunities. Dr. Masdeu will be searching for an associate editor to handle this new section. He thanked the editorial board, the Board of Directors, Blackwell and members.

### **Fellowship/Training Committee Report**

Dr. Mechtler reported that they are in the process of obtaining United Council of Neurological Subspecialties (UCNS) accreditation for existing fellowships. In addition he asked attendees to consider developing new fellowships. The UCNS is meeting in May and will be reviewing fellowships at that time. The first UCNS MRI examination will be given in February.

Dr. Mechtler announced a new long distance learning tool that will be implemented early 2008. He thanked Dr. Lindzen for researching the *Go To Meetings* platform. The service is reasonably priced and a schedule for Friday meetings is being developed. It is hoped that this will be a tool to increase recruitment of new members.

The annual awards were presented. Dr. Greenberg presented the John and Sophie Prockop Memorial Lectureship to Dr. Satnam Nijjar. Dr. Qureshi presented the Qureshi Award to Dr. Qaisar Shah. Dr. Gomez presented the Trainee Travel Awards to Drs. Alberto Maud, Dhruvil Pandya and Tobias Loddenkemper.

Dr. Bakshi announced that the 2007-2008 Kinkel Fellowship had been presented to Dr. Eric Potts. Dr. Potts came from the University of Rochester and is doing his fellowship with Dr. Capone in Virginia.

### **New Business**

Dr. Farrukh Qureshi said that current members owe the opportunities open to them to the founders of ASN. He pledged to support the membership of three residents for this year. He will be in touch with the Executive Office after the annual meeting to arrange this.

There being no further business, the meeting was adjourned.

Respectfully submitted,

Kris McDowell  
Associate Executive Director

KAM:slf

## 2009 Faculty & Program Committee Disclosures

In accordance with the guidelines of the Accreditation Council for Continuing Medical Education (ACCME), ASN requires disclosure of any interests or affiliations with corporate organizations of Faculty (indicated below with F) and Program Committee Members (indicated below with PC).

Reeta Achari, MD	(F, PC) No Relationships
Andrei Alexandrov, MD, RVT	(F, PC) Consultant: ImaRx Therapeutics; Speaker: Genentech
John Chawluk, MD	(F, PC) No Relationships
Patrick Capone, MD, PhD	(F) Principal Investigator: Photo Thera Inc., H. Lundbeck A/S, United Biosource Corporation
Neeraj Dubey, MD	(F, PC) No Relationships
Ed Eichorn	(F) No Relationships
Zsolt Garami, MD	(F) No Relationships
Camilo Gomez, MD	(F, PC) Scientific Advisor: Alsius Corporation; Guidant Corporation; Cordis Corporation; W.L. Gore, Inc; Accumetrics, Inc. Consultant: Alsius Corporation; Guidant Corporation; Boston-Scientific Corporation; Bristol-Myers Squibb/Sanofi Pharmaceuticals; Investigator: Alsius Corporation; Guidant Corporation; Boston-Scientific Corporation; Cordis Corporation; CoAxia, Inc.; Accumetrics, Inc.; Abbot Vascular; Bristol-Myers Squibb/Sanofi Pharmaceuticals; Abbott Laboratories, Inc.; Parke-Davis Laboratories; Astra-Zeneca Pharmaceutical; Bayer Pharmaceuticals; Speaker: Bristol-Myers Squibb/Sanofi Pharmaceuticals; Abbott Laboratories, Inc.; Boehringer-Ingelheim Pharmaceuticals; Solvay Pharmaceuticals; USP Pharma.
Geoffrey Hartwig, MD	(F) No Relationships
Michael Hutchinson, MD, PhD	(F) No Relationships
Tudor Jovin, MD	(F) No Relationships
Jawad Kirmani, MD	(F) No Relationships
Ruben Kuzniecky, MD	(F) No Relationships
David Liebeskind, MD	(F, PC) Consultant: CoAxia, Inc., Concentric Medical Inc.
Bret Lindsay, MD	(F, PC) Speaker: Teva, Forrest; Consultant: Biogen
Eric Lindzen, MD, PhD	(F) No Relationships
Joseph Masdeu, MD, PhD	(F) No Relationships
Laszlo Mechtler, MD	(F, PC) Speaker: Pfizer, GlaxoSmithKline, Merck, Ortho McNeil, Schering-Plough, UCB Pharma, INC.
Mircea Morariu, MD	(F, PC) Speaker: Glaxo Smith Kline; Pfizer; Boehringer-Ingelheim Pharmaceuticals
Michael Moseley, PhD	(F) No Relationships
Erasmio Passaro, MD	(F, PC) Speaker: Pfizer, GlaxoSmithKline, UCB, Takeda
Joseph Polak, MD, MPH	(F) No Relationships
William Preston, MD, FAAN	(F) Investigator: Eisai Pharmaceutical Co.
Adnan Qureshi, MD	(F, PC) No Relationships
Alexander Razumovsky, PhD	(F, PC) FTE: Sentient Neurocare Services, Inc.
Alice Robinson, MD	(F) No Relationships
Brian Ross, MD	(F) Speaker: GE Healthcare
Steven Shook, MD	(F) No Relationships
Michael Sloan, MD	(F, PC) No Relationships
Gabriella Sztatmary, MD, PhD	(F) No Relationships
Charles Tegeler, MD	(F, PC) Speaker: Sanofi-Aventis
Osama Zaidat, MD	(F) Consultant: Boston Scientific

### CME CERTIFICATES AND EVALUATIONS

CME certificates will be issued after the conclusion of the 2009 Annual Meeting. In order to receive your CME certificate you will need to submit an evaluation form for each course attended. In an ongoing effort to move to paperless format, evaluations will only be available online. All meeting attendees will receive an email after the meeting with a link to the evaluations.

### CONTINUING MEDICAL EDUCATION CREDITS (CME)

This activity has been planned and implemented in accordance with the Essential Areas and Policies of the Accreditation Council for Continuing Medical Education (ACCME). The American Society of Neuroimaging is accredited by the ACCME to provide continuing medical education for physicians. The material presented at the 32nd Annual Meeting is appropriate for neurologists, radiologists, and other physicians and health care professionals involved in the diagnosis and treatment of patients with neurologic disease.

The ASN designates this educational activity for a maximum of 24.00 AMA PRA Category 1 Credit(s)<sup>TM</sup>. Physicians should only claim credit commensurate with the extent of their participation in the activity.

The American Society of Neuroimaging takes responsibility for the content, quality, and scientific integrity of this CME activity.

Please note: You will only receive CME credits for the courses for which you have registered.

#### **AMERICAN SOCIETY OF NEUROIMAGING CME MISSION STATEMENT**

The American Society of Neuroimaging (ASN) is an international professional organization representing neurologists, neurosurgeons, neuroradiologists, and other neuroscientists who are dedicated to the advancement of any technique used to image the nervous system. Its purpose is to promote the highest standards of neuroimaging in clinical practice, thereby furthering ongoing improvement in the delivery of medical care. ASN's Annual Meeting educational activities are planned to meet the educational needs of physicians in practice and training in regard to the study of the nervous system with techniques including x-ray angiography and computed tomography, nuclear magnetic resonance, ultrasound, positron emission tomography and single photon emission computed tomography and near infra-red spectroscopy. Emphasis is placed on the correlation of the clinical data with information derived from the various methods used to image the nervous system and related structures (integrated neuroimaging) and on the updating of algorithms leading to a cost effective and efficient use of imaging modalities for the different disorders of the nervous system. The Society further supports and promotes Fellowships, Preceptorships, Tutorials, and Seminars related to neuroimaging held throughout the country. The courses address advances in the role of MRI, CT, and Neurosonology in Neurology and are designed to help practitioners and trainees improve their interpretation skills.

## 32nd Annual Meeting Sponsors

The American Society of Neuroimaging thanks Philips Healthcare for the generous support of the Onsite Program.

# PHILIPS

sense and simplicity

The American Society of Neuroimaging extends special thanks to the following companies for exhibiting at the meeting:

**Cardinal Health**

**Compumedics USA, Ltd.**

**Elsevier – Saunders – Mosby**

**Intersocietal Accreditation Commission (IAC)**

**Philips Healthcare**

**PhotoDetection Systems**

**Spencer Technologies**

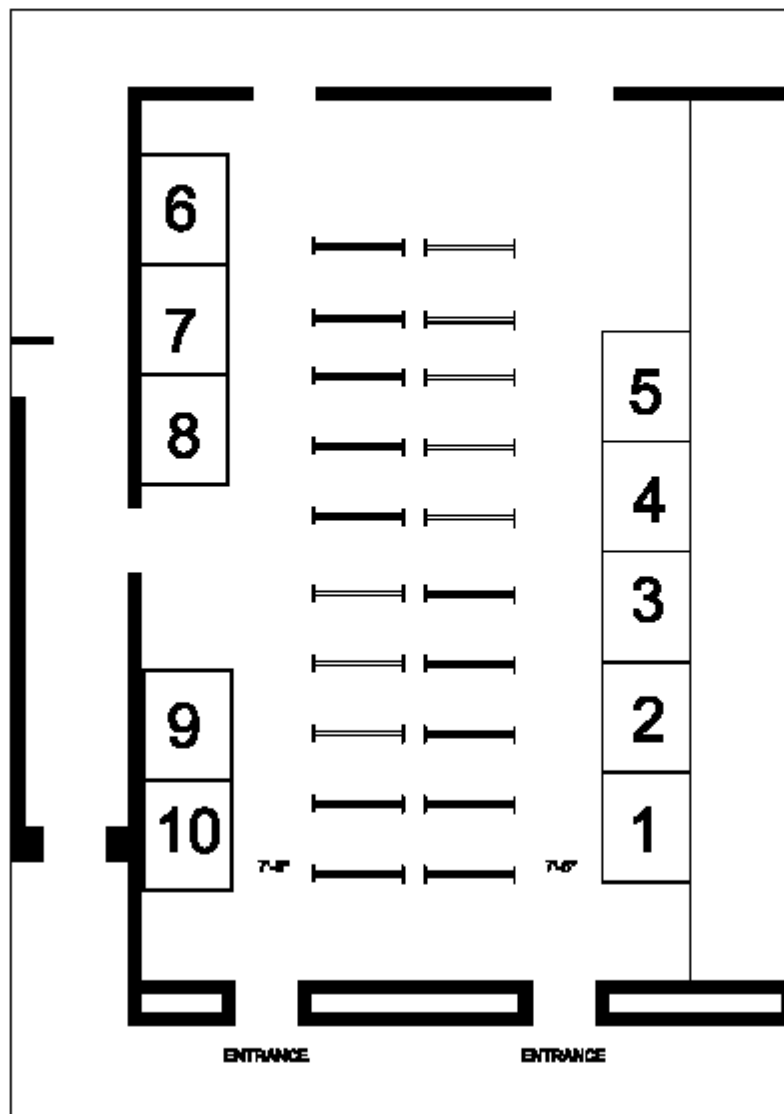
**Wiley-Blackwell**

# American Society of Neuroimaging

January 22-23, 2009

Hilton Hotel - Lake Buena Vista, FL

International Ballroom North



10 - 8 x 10 booths  
20 - poster boards

current plan as of 12.29.08



## 32nd Annual Meeting Exhibitors

### BOOTH NUMBER 1: Cardinal Healthcare (Formerly VIASYS Healthcare)

*VIASYS Healthcare is now a Cardinal Health Company*

Cardinal Health offers Peripheral Vascular systems with comprehensive diagnostic capabilities including patented TFI for time-efficient screening of PAD. Our Transcranial Doppler systems enable clinicians to screen and diagnose stroke. SONARA and SONARA/tek digital TCD systems feature exclusive 250-gate M-Mode display, velocity profile, configurable display and much more!

**Company Representatives:** Gwyn Eiler, Keith Holmes, Donalee Davis

### BOOTH NUMBER 2: Spencer Technologies

Spencer Technologies' ST3 Digital Transcranial Doppler features HDO™, High Density Oversampling. HDO™ technology provides an exceptionally high fidelity Power M-mode display to enable rapid window and vessel location. This simplifies neurovascular diagnostic and RLS/PFO examinations. HDO™ is the state of the art in digital TCD processing, available only from Spencer Technologies.

### BOOTH NUMBER 3: Intersocietal Accreditation Commission (IAC)

The Intersocietal Accreditation Commission (IAC) is comprised of several accrediting bodies. Of specific interest to neurologists are the ICAVL ([www.icavl.org](http://www.icavl.org)) providing accreditation for noninvasive vascular testing, the ICAMRL ([www.icamrl.org](http://www.icamrl.org)) providing accreditation for magnetic resonance, and ICACTL ([www.icactl.org](http://www.icactl.org)) providing accreditation for computed tomography. Also, stop by to learn more about our webcast series Accreditation on Demand.

**Company Representatives:** Lawrence Williams, Sandy Katanick, Mary Lally

### BOOTH NUMBER 5: PhotoDetection Systems

PhotoDetection Systems develops and markets a powerful NeuroPET™\* system, which has been designed for the neuro-imaging community. Its compact design provides the image quality of a large PET scanner with only ¼ of the dose and for ½ the cost. ([www.photodetection.com](http://www.photodetection.com))

\* available for research use only until FDA clearance

**Company Representatives:** Bill Mitchell

### BOOTH NUMBER 6: Elsevier – Saunders - Mosby

Elsevier is a leading publisher of medical and surgical textbooks, periodicals and web based educational references.

**Company Representatives:** Tony Norton, Bill Diver

### BOOTH NUMBER 7: Compumedics USA

Compumedics DWL™ digital transcranial Doppler systems have everything! DWL offers diagnostic routines, advanced monitoring software, digital M-Mode, Embolic event detection, microvascular and multi-frequency transducer support in portable, powerful system configurations. Ask about the NEW digital Multi-Dop X4 and EZ-Dop systems and learn how to escape expensive PC obsolescence with Doppler-Box™. [www.Compumedics.com](http://www.Compumedics.com)

**Company Representatives:** Jerry Barton, Tom Lorick

**BOOTH NUMBER 8: American Society of Neuroimaging**

The American Society of Neuroimaging (ASN) is an international, professional organization representing neurologists, neurosurgeons, neuroradiologists and other neuroscientists who are dedicated to the advancement of techniques used to evaluate the nervous system. [www.asnweb.org](http://www.asnweb.org)

**BOOTH NUMBER 9: Wiley-Blackwell**

Wiley published an enormous range of top quality consumer, professional, educational and research material. Wiley-Blackwell, the scientific, technical, medical and scholarly publishing business of John Wiley & Sons, is the leading society publisher and offers libraries peer-reviewed primary research and evidence based medicine across 1250 online journals, books, reference works and databases. For more information, visit [www.wiley.com](http://www.wiley.com).

**Company Representatives:** Christopher Breslin, Taryn Goggin

**BOOTH NUMBER 10: Philips Healthcare**

Philips Healthcare welcomes members and is proud to sponsor the 32<sup>nd</sup> Annual ASN meeting. This year we will feature our Elite Clinical Solutions for Neuro. This solution provides a comprehensive set of tools for Neuro MRI needs and is available on our 3.0T, 1.5T and HFO systems. We will also feature our exclusive SmartExam technology for the brain and spine this allows for one click planning, scanning and post processing.

**Company Representatives:** Dirk Noel

## 2009 Award Winners

*Awards will be presented Saturday, January 24, 2009 during the Presidential Address and Awards Luncheon.*

### **John and Sophie Prockop Memorial Lectureship**

The John and Sophie Memorial Lectureship was established to enhance the scholarly and educational missions of the Society by honoring outstanding contributions made to the Society's peer-reviewed journal, the *Journal of Neuroimaging*. The recipient of the Lectureship is the first author of a manuscript published in the journal that has been judged to have outstanding value to the development and success of the journal, or the highest quality manuscript published in the prior year as judged by the American Society of Neuroimaging Education Foundation Board of Directors.

#### **2009 John and Sophie Prockop Memorial Lectureship Recipient**

Stafford Conway, MD  
Birmingham, AL

*Quantitative Magnetic Resonance Angiography of the Cerebrovasculature in Physiologic and Pathologic States*  
(Volume 18 Issue 1 Pages 34-37, January 2008)

### **Qureshi Award**

The Qureshi Award is for the best manuscript based on research in diagnostic angiography or endovascular procedures.

#### **2009 Qureshi Award Recipient**

Jefferson Miley, MD  
University of Minnesota  
Department of Neurology  
Minneapolis, MN

*Endovascular Retrieval of a Premature Covered Stent Deployment: Technical Report*

### **Oldendorf Award**

The Oldendorf Award is for the best manuscript based on research in CT, MRI, SPECT or PET.

#### **2009 Oldendorf Award Recipient**

Mohit Neema, MD  
HMS/BWH  
Department of Neurology  
Boston, MA

*3T MRI Relaxometry Detects T2 Prolongation in the Cerebral Normal-Appearing White Matter in Multiple Sclerosis*

### **Trainee Travel Awards**

The Trainee Travel awards are presented to the two top-ranked abstracts submitted by a resident/fellow for poster presentations.

#### **2009 Resident Travel Award Recipients**

Sara Khan, MD  
Cleveland Clinic  
Cleveland, Ohio  
Poster #16

*Syrinx Formation after Cervical Epidural Injection: A Case Report*

Mr. Rizwan Bashir  
USF College of Medicine  
Miami, Florida  
Poster #9

*Persistent Vegetative State: A Clinical-Neuroimaging-Pathological Correlation*

## 1. An Unusual Case of Spinal Cord Infarct Months after Cardiac Valve Surgery Revealed by MRI and Spinal Angiography

Edward Tay, Rishi Gupta  
Cleveland Clinic, Cleveland, OH, United States

**Introduction:** Spinal cord infarct is much less frequent than cerebral infarction, accounting for only 1% of all strokes. Most cases of spinal cord ischemia have been associated with aortic surgery or prolonged arterial hypotension. We describe a case report of spinal cord ischemia complicated by haemorrhage, initially thought to be a case of transverse myelitis.

**Patients (or Materials) and Methods:** A 42 year old Kuwaiti woman with history of cardiac valve surgery 2 months ago, on anticoagulation, presented with several day history of lower extremity weakness and bowel and bladder incontinence. Exam was significant for a T8 sensory level, flaccid paraplegia, and loss of LE reflexes. Infectious and inflammatory workup was negative. MRI spine and spinal angiogram were done which revealed the diagnosis. We present a case of spinal cord ischemia complicated by haemorrhage found on imaging and looked at the relevant literature.

**Results:** MRI T1 thoracic and lumbar spine revealed blood products in the lower thoracic and entire lumbar spine. A spinal angiogram revealed the absence of the artery of Adamkiewicz. CT abdomen showed splenic and liver infarcts consistent with thromboembolic disease.

**Conclusion:** MRI imaging can be helpful in the diagnosis of spinal cord ischemia. Sagittal and axial T2 weighted images are considered the most useful. Spinal angiography can also be of use in diagnosing AVMs of the spine and spinal artery occlusion. Certain clinical features are associated with different areas of the spinal cord. This combined with MR imaging and selective use of spinal angiography can help lead to a definitive diagnosis.

## 2. Safety of Administration Intravenous Thrombolytics Prior to Endovascular Treatment of Acute Ischemic Stroke

Haitham Hussein<sup>1</sup>, Yousef Mohammad<sup>2</sup>, M Fareed Suri<sup>1</sup>, Adnan Qureshi<sup>1</sup>

<sup>1</sup>Zeenat Qureshi Stroke Research Center, University of Minnesota, Minneapolis, MN, United States, <sup>2</sup>of Neurology, Ohio State University, Columbus, Ohio, United States

**Introduction:** Intra-arterial thrombolysis (IAT) after initiation of intravenous thrombolysis is one of the

treatment protocols for acute ischemic stroke. We determined the safety of this practice.

### Patients (or Materials) and Methods:

We reviewed clinical charts at 2 academic centers for all patients treated with IAT. National Institute of Health Stroke Scale score (NIHSS) was determined before treatment, 24 hours and at 7 days (discharge), according to a prospective protocol. Intracerebral hemorrhage (ICH) was evaluated by serial computed tomography. Logistic regression multivariate analysis was performed to determine the independent effect of combination treatment on rate of intracerebral hemorrhage (ICH) or mortality.

**Results:** A total of 206 patients were treated using IAT. Mean age (+/- SD) was 65(+/-14) and 51% were male. IVT was used in 35(17%) patients. Time to microcatheter placement was shorter (242 [ ] 64 vs 321 [ ] 194 minutes) for patients treated with IVT. Patients treated with IVT 'bridging' to IAT had lower rates of symptomatic ICH (2.9% vs 8.2%, p = 0.48) and mortality (8.6% vs 15.8%, p = 0.4) when compared to IAT group. Rate of neurological improvement defines as improvement in NIHSS of 4 or more points was higher in patients treated with IVT 'bridging' protocol (91% vs 62%) compared to IAT. In patients treated with IVT 'bridging' protocol, there was no increased risk of ICH (Odds ratio [OR] 1.13, p = 0.3), symptomatic ICH (OR 0.9, p = 0.3) or mortality (OR 0.3, p = 0.6) after adjustment for age, sex, time to catheterization, baseline NIHSS and occlusion grade.

**Conclusion:** Administration of IVT prior to endovascular treatment is appears safe and effective.

## 3. Prognostic Factors of Ophthalmoparesis in

### Carotid-Cavernous Fistula

Young Noh, Keun-Hwa Jung, Hee-Kwon Park, Jae-Kyu Roh

Seoul National University Hospital, Seoul, Korea, Republic of

**Introduction:** Ophthalmoparesis is one of the major symptoms of carotid-cavernous fistula (CCF). The aim of this study is to define the factors which influence the outcome of endovascular embolization for patients with CCF presenting ophthalmoparesis.

### Patients (or Materials) and Methods:

Patients who presented ophthalmoparesis among consecutive patients diagnosed as CCF by conventional angiography were enrolled in this study. They received endovascular treatment via either transvenous, transarterial or both

approaches. We divided ophthalmoparesis into three types: isolated sixth nerve palsy; third nerve palsy; multiple cranial nerve palsy. Clinical and radiological factors associated with endovascular outcome were assessed.

**Results:** Among 54 study subjects, 28 recovered early (<1 month) and 26 did late or incompletely. Post-embolization state was strongly associated with early recovery (p = 0.057, complete interruption: 65.5%; minor residual shunts: 42.1%; significant residual shunts: 16.7%). Moreover, the early recovery was associated with a more gradual onset (p = 0.064), and ophthalmoparesis types (p = 0.039, sixth cranial nerve palsy: 70.8%; third cranial nerve palsy: 50.0%; multiple cranial nerve palsy: 33.3%). When the data were analyzed excluding the cases with significant residual shunts after endovascular embolization (n = 48), ophthalmoparesis type remained significantly associated with early recovery (p = 0.015). Among patients with third nerve palsy, compressive type was more significantly associated with early recovery, compared to ischemic type (p = 0.017, 53.8% vs 0%).

**Conclusion:** Symptom presentation type, ophthalmoparesis type and post-embolic vascular state can be significant independent predictors for the endovascular outcome of ophthalmoparesis in CCF.

## 4. Sjogren's Syndrome and Multifocal Intracranial Vasculopathy

Andrew Russman  
Henry Ford Hospital, Detroit, Michigan, United States

**Introduction:** To characterize the management challenges clinicians may face in a patient with multifocal intracranial vasculopathy, and a history of Sjogren's syndrome.

### Patients (or Materials) and Methods:

A 45-year-old Asian-French woman with a history of rare migraines, microscopic hematuria, and dry eyes presents with multiple thirty-minute episodes of sudden onset, severe occipital headaches. Her neurological examination was normal. Cerebral angiography revealed significant multifocal intracranial stenoses in both the anterior and posterior circulation. Brain MRI was normal. Cerebrospinal fluid analysis (CSF) showed no evidence of pleocytosis. Serum SS-B (La Antibody) was positive. Schirmer's Test was positive.

**Results:** This patient's clinical presentation suggested a possible Call-Fleming syndrome. Her pre-existing clinical symptoms and subsequent laboratory studies met

criteria for Sjogren's syndrome. Her headaches resolved soon after starting verapamil and oral steroids. Prednisone was slowly tapered over a period of 4 weeks. Repeat contrast MR angiography at 8 weeks, and 24 weeks revealed stable areas of moderate to severe multifocal intracranial stenosis. The patient's clinical symptoms remained quiescent. Verapamil was self-stopped by the patient due to constipation after 24 weeks. Contrast MR angiography was repeated at 36 weeks, showing complete resolution of the prior areas of multifocal intracranial stenosis. The clinical and imaging pattern seen in this patient may be consistent with benign angiopathy of the central nervous system (BACNS). **Conclusion:** Despite the presence of Sjogren's syndrome, a non-inflammatory CSF in patients presenting with thunderclap headaches and a prolonged period of multifocal intracranial vasculopathy, may indicate a clinical course more consistent with BACNS.

### 5. Endovascular Treatment of Acute Ischemic Stroke Due to Cocaine Induced Cerebral Vasospasm

Ammar AlKawi, Ahmed El-Gengaihy, Akram Shhadeh, Steven Hoover UMDNJ, Newark, NJ, United States

**Introduction:** Cocaine abuse increases the risk of ischemic stroke. The increased levels of extracellular monoamines result in cerebral vasospasm. We report clinical and radiological improvement of cocaine induced vasospasm and stroke in two patients after intraarterial nicardipine.

#### **Patients (or Materials) and Methods:**

We report 2 patients who presented within 3–6 hours of onset of stroke. A urine drug screen was performed on presentation. An emergent conventional cerebral angiography and intraarterial nicardipine were done after detection of intracranial vasospasm. Follow-up CT and MRI were performed at 24 hours. Clinical improvement was monitored using the NIHSS and modified Ranken Scale (mRS).

**Results:** Both patients had positive urine toxicology screen for cocaine.

#### Case 1

The patient had an initial NIHSS of 32. Cerebral angiography revealed basilar artery vasospasm. Spasm and distal flow improved after injection of 3.5 mg of intraarterial nicardipine. At discharge, the patient's NIHSS score improved to 4 and mRS was 2. MRI showed midbrain infarction.

#### Case 2

The patient had an initial NIHSS of 22. Cerebral angiography revealed multiple areas of vasospasm in the left intracranial internal carotid/middle cerebral arteries. After injection of 7.5 mg intraarterial nicardipine vasospasm and distal flow improved.

Discharge NIHSS and mRS were 0. MRI showed a small infarction in the left middle and posterior cerebral arteries watershed zone.

**Conclusion:** Intraarterial nicardipine can be used to reverse cocaine induced cerebral vasospasm and treat the acute ischemic stroke. However, this series is limited and further studies are required to determine the effectiveness of this therapeutic modality.

### 6. Endovascular Retrieval of a Premature Covered Stent Deployment; Technical Report

Jefferson T. Miley MD, Gustavo J. Rodriguez MD and Ramachandra P. Tummala MD Zeenat-Qureshi Stroke Research Center, University of Minnesota, Minneapolis, MN

**Introduction:** Several techniques have been reported to address different endovascular device failures. We report the case of a premature deployment of a covered balloon mounted stent during endovascular repair of a post-traumatic direct carotid cavernous fistula (CCF). **Case description:** A 50 year-old male suffered a 20 ft fall resulting in loss of consciousness, wrist, rib and facial fractures. Six weeks later, he presented at our institution with a one week history of visual complaints.

Examination demonstrated decreased left visual acuity, proptosis, chemosis, limited eye movements and cranial/orbit bruit. Computed Tomography demonstrated fractures in the left zygomatic arch and left lateral orbital wall. Cerebral angiography demonstrated a direct left CCF and endovascular repair was planned. A 7 French Brite Tip guide catheter was positioned in the distal cervical left internal carotid artery (ICA). A microcatheter (Excelsior SL 10) was advanced over a microwire (Transcend 14) into the left supraclinoid ICA. The microwire was exchanged for a 300 cm Luge microwire. The microcatheter was exchanged for a 5.0 × 19 mm Graft-Master JOSTENT. Once into the petrous segment, increased resistance was encountered and the stent was withdrawn resulting in premature deployment.

A 3 × 9 mm Maverick balloon was advanced over a Transcend 14 microwire through the stent lumen and once distal, the balloon was inflated under fluoroscopy and slowly pulled back in contact with the stent. Then the wire, balloon, stent and guide catheter were withdrawn as a unit.

**Conclusion:** Endovascular balloon assisted retrieval of a premature balloon mounted stent deployment can be safely performed.

### 7. Transient Locked in Syndrome due to Basilar Occlusion

Daniel Ontaneda, Steven Shook

Cleveland Clinic, Cleveland, Ohio, United States

**Introduction:** The locked in syndrome is classically described as quadriplegia and anarthria, with preserved consciousness. Basilar occlusion has been described as a cause of LIS and has typically been described as carrying a very high mortality rate. Here we present a case of basilar thrombosis which manifested with a transient locked in syndrome.

**Materials and Methods:** A 74 year old female with a past medical history of hypertension and interstitial lung disease, presented with a 10 minute episode of peri-oral numbness and tingling in both upper extremities. CT/CTA of the brain and neck revealed a high grade proximal basilar stenosis. She experienced ongoing episodes of transient double vision. Approximately 3 months after her initial presentation she developed the acute onset of dysphagia and inability to speak followed by profound weakness in all 4 extremities evolving to quadriplegia. She was taken to the ED and intubated. The patient had intact memory of all events at that time. She recovered motor power over the next 2 hours and was extubated. She made a complete recovery.

**Results:** MRI/MRA of the brain showed no DWI abnormalities and a loss of flow void in the proximal basilar artery. CTA and angiography confirmed a proximal basilar occlusion. **Conclusion:** The case illustrated here is a unique presentation of basilar artery occlusion. Transient locked in syndrome is a rare condition, and when present points to non vascular etiologies, however our case illustrates the significant variability in presentation of locked in syndrome, and also of TIA.

### 8. Qualitative Evaluation of a Novel Noise-Reduction Algorithm Developed to Improve Contrast Resolution in Non-Contrast Head CT Studies

David Weinreb<sup>1</sup>, Alisa Gean<sup>2</sup>

<sup>1</sup>Hospital of Saint Raphael, New Haven, CT, United States, <sup>2</sup>University of California, San Francisco, San Francisco, CA, United States

**Introduction:** The objective of the present study is to evaluate a novel algorithm developed to reduce noise and thereby increase contrast resolution in non-contrast head CT studies performed at low radiation doses.

**Methods:** CT reconstruction algorithms use a filtered-backprojection process wherein the filter strength is selected by the user to offer images that trade off noise with spatial resolution. We developed a novel post-reconstruction algorithm that suppresses the noise in the image without degrading spatial resolution. This is achieved by segmenting the image into groups of pixels and then

filtering within each group. We recruited four neuroradiologists, all of whom were unfamiliar with the algorithm, to review 50 unique cases, comparing unprocessed and processed cases. These cases, acquired at doses of 4 Rads, included both pediatric and adult patients and demonstrate a wide spectrum of intra-cranial pathology, including ischemic stroke, intraventricular hemorrhage and subdural hematoma.

**Results:** Two of the four radiologists “preferred” the processed images in all cases. The other two radiologists preferred the processed images in 49/50 and 48/50 cases, respectively. The contrast resolution was described as “improved” in 48/50 cases (95%, range 84 – 100%). Spatial resolution was felt to be “degraded” in only two cases by a single radiologist.

**Conclusions:** This novel noise-reduction algorithm improves contrast resolution of low-dose non-contrast head CT studies without affecting spatial resolution. This algorithm may ultimately allow head CT images to be effectively performed at lower radiation doses, which would be particularly desirable in the pediatric population.

**9. Persistent Vegetative State: A Clinical-Neuroimaging-Pathological Correlation** Rizwan Bashir, Leon Prockop  
USF College of Medicine, Tampa, FL, United States

**Introduction:** Accurately predicting the chances of awakening following cardio respiratory arrest is important to help families make decisions about continued medical care.

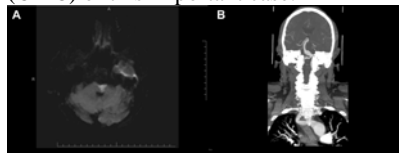
**Patients (or Materials) and Methods:** At age 25 on 2/25/1990 a woman suffered cardiac arrest causing severe hypoxic encephalopathy.

**Results:** During subsequent months, she exhibited no evidence of higher cortical function.

Electroencephalograms showed no electrical activity. Brain CT scans demonstrated severe central and cortical atrophy, ie. hydrocephalus ex vacuo, estimated visually with less than 50% of brain tissue remaining. None appeared to be normal by CT criteria. Nonetheless, her condition provoked controversy whereby her parents and some members of our legislative and executive branches favored maintenance of nasogastric feedings while her husband and others did not. After such were discontinued, her breathing and heart ceased. An autopsy performed on 4/01/2005 described a brain weighing 615 G. Brain sulci were widened and gyri, narrow. There was prominent diffuse ventriculomegaly (hydrocephalus *ex vacuo*).

**Conclusion:** In the opinion of the pathologist, the patient suffered from complications of Anoxic

Encephalopathy, which is consistent with brain CT findings from over a decade earlier. This is the first clinical/imaging/pathological correlation (CIPC) of this important case.



**10. Millard-Gubler Syndrome Associated with a Thrombosed Basilar Artery Aneurysm** Brian Silver, Aashish Patel

Henry Ford Hospital, Detroit, MI, United States

**Introduction:** Millard-Gubler syndrome, also known as facial hemiplegia alternans, was described in 1856 to explain crossed hemiplegia findings (ipsilateral facial palsy and contralateral hemiparesis). Typically, it is associated with small vessel disease. We describe a patient with MGS with an associated thrombosed basilar artery aneurysm.

**Patients (or Materials) and Methods:** A 63 year old man presented with right arm and leg weakness. He reported an occipital headache starting ten minutes prior to the onset of symptoms. Neurological examination demonstrated severe dysarthria, left facial palsy, inability to abduct the left eye past midline, and right arm and leg hemiparesis. Diffusion-weighted MRI imaging of the brain showed an acute infarction of the left ventrolateral pons. (Figure A) CT angiography of the head showed a fusiform aneurysm of the basilar artery arising from the vertebrobasilar junction and extending to the midportion of the basilar artery. (Figure B) The aneurysm measured 1.2 cm × 2.4 cm and was associated with a mural thrombus.

**Results:** Because of the location and size of the aneurysm as well as associated mural thrombus, surgery and/or an interventional approach were not performed. He was treated with aspirin, gemfibrozil, and simvastatin. The patient was discharged to rehabilitation and continues to make recovery six months later.

**Conclusion:** Initial descriptions of MGS did not include ipsilateral abducens palsy as part of the syndrome but, based on later reports, ipsilateral abducens palsy was included as part of the definition. Foville syndrome is similar to MGS because of ipsilateral facial palsy and contralateral hemiparesis; however, there is an associated ipsilateral conjugate gaze paresis which distinguishes the two syndromes. To our knowledge, MGS has not been previously reported in association with a thrombosed basilar artery aneurysm.

**11. An Eye Ball Estimation of Intracerebral Hemorrhages** Jefferson T. Miley MD, Haitham M. Hussein MD, Adam Todd MD, Erik Uhlmann MD, Douglas A. ValentaMD, Osman S. Kozak MD, Gabriela Vazquez PhD and Mustapha A. Ezzeddine MD  
Zeenat Qureshi Stroke Research Center, University of Minnesota, Minneapolis, MN, United States

**Introduction:** Volume determination of spontaneous intracerebral hemorrhages (ICH) in combination with clinical features are predictors of morbidity and mortality. Methods to estimate ICH requires mathematical calculation or special software application. Our objective is to determine if the patient’s eye ball (EB) on computed tomography (CT) can be used to estimate the ICH volume. **Methods:** Consecutive patients with ICH on CT were included. Individual ICH volume and EB volumes were calculated using MIPAV (Medical Image Processing And Visualization). Five observers reviewed the images and were asked to estimate the number of EB that would fit into the ICH excluding intraventricular hemorrhage and to grossly allocate the ICH volume into one of three categories; 0–30 cc, 31–60 cc or >61 cc. Linear association between the true and the estimated number of EB was assessed using a linear mixed model. Intra-class correlation (ICC) and weighted kappa (*k*) was also calculated.

**Results:** Thirty seven CT scans with ICH (0–30 cc n = 27; 31–60 cc n = 5; >61 cc n = 5) were reviewed. Overall ICC volume estimation was 0.27 when using the EB method. Subgroups of 0–30 cc, 31–60 cc and >61 cc, ICC values were 0.17, 0.55 and 0.78 respectively. Observers underestimated the number of EB as the volume of ICH increased (slope = 0.44 se = 0.186). There was moderate interobserver agreement for gross ICH volume estimation (*k* = 0.58). The raters correctly allocated hemorrhages in 0–30 cc, 31–60 cc and >61 cc in 98%, 30% and 54% of the cases, respectively. **Conclusions:** Eye ball and gross volume estimation are reliable methods for volume estimation in ICH of less than 30 cc.

**12. 3T MRI Relaxometry Detects T2 Prolongation in the Cerebral Normal-Appearing White Matter in Multiple Sclerosis** Mohit Neema<sup>1</sup>, Daniel Goldberg<sup>2</sup>, Zachary Guss<sup>1</sup>, Brian Healy<sup>1</sup>, Charles Guttmann<sup>2</sup>, Maria Houtchens<sup>1</sup>, Howard Weiner<sup>1</sup>, Mark Horsfield<sup>3</sup>, David Hackney<sup>4</sup>, David Alsop<sup>4</sup>, Rohit Bakshi<sup>1</sup>  
<sup>1</sup>Departments of Neurology, Brigham and Women’s Hospital, Partners MS Center, Harvard Medical School, Boston, United States, <sup>2</sup>Departments of Radiology, Brigham and Women’s

Hospital, Harvard Medical School, Boston, United States, <sup>3</sup>Department of Cardiovascular Sciences, University of Leicester, Leicester, United Kingdom, <sup>4</sup>Department of Radiology, Beth Israel Deaconess Hospital, Harvard Medical School, Boston, United States

**Introduction:** MRI at 3T has increased sensitivity in detecting overt multiple sclerosis (MS) brain lesions; a growing body of data suggests clinically relevant damage occurs in the normal-appearing white matter (NAWM).

**Patients (or Materials) and Methods:**

In this pilot study, we tested a novel pulse sequence to determine whether 3T MRI spin-spin relaxometry detected damage in NAWM of MS patients (n = 13) vs. age-matched normal controls [(NL) (n = 11)]. Baseline characteristics of the MS group were: age (mean  $\pm$  SD) 42.5  $\pm$  5.4 (range 33–51 years), disease duration 9.0  $\pm$  6.3 (range 1–22 years), Expanded Disability Status Scale score 2.5  $\pm$  1.7 (range 1–6.5), 11 relapsing-remitting, 1 primary progressive, and 1 secondary progressive. R2 (= 1/T2) brain maps, created from 3D fast spin-echo T2 prepared images acquired at 3T, were segmented to derive global transverse relaxation rate (R2) histograms and the regional R2. The regional NAWM areas were frontal lobe, parietal lobe, and the genu and splenium of the corpus callosum.

**Results:** Mean NAWM R2 was lower (indicating T2 prolongation) in MS than NL in the whole brain (p = 0.00047), frontal NAWM (p = 0.00023), parietal NAWM (p = 0.0088) and callosal genu (p = 0.0026). Similarly, R2 histogram peak position was lower in NAWM in MS than NL in the whole brain (p = 0.019).

**Conclusion:** Our preliminary results suggest that a novel 3D FSE pulse sequence at 3T, used to derive R2 relaxometry can detect tissue damage in the global and regional cerebral NAWM of MS patients that is missed by conventional lesion measures. Such findings may represent demyelination, inflammation, glial proliferation and axonal loss.

**13. Signal Intensity of Magnetic Resonance Angiography of the Head Predicts Computerized Tomography Perfusion of the Brain in Patients with Cervical Carotid Disease**

Gustavo J. Rodriguez MD, Jefferson T. Miley MD, Alberto Maud MD, Osman S. Kozak MD, Robert A. Taylor MD and Qureshi I. Adnan MD Zeenat-Qureshi Stroke Research Center. University of Minnesota. Minneapolis, MN

**Introduction:** Cervical carotid disease (CCD) with decreased brain perfusion is thought to be a risk factor for

ischemic stroke; however perfusion studies are not commonly available. We hypothesize that asymmetries in signal intensity of the head magnetic resonance imaging (MRA) can predict asymmetries in brain computerized tomography (CT) perfusion in patients with CCD.

**Methods:** Consecutive patients with severe CCD that underwent stent placement at our institution were selected (October 2006–August 2008). Those with preoperative MRA and CT perfusion were included. Simple visualization of head MRA (3D Time of flight) was performed to detect asymmetries in the signal intensity of the anterior circulation vessels. In addition, the diameter (mm) of the distal internal carotid artery (ICA), and proximal middle (MCA) and anterior cerebral (ACA) arteries were measured. The association between side asymmetries in signal intensity and side vessel diameter on head MRA with asymmetries in the brain CT perfusion was studied.

**Results:** A total of 71 patients underwent stent placement and 23 fulfilled criteria. By simple visualization analysis we obtained a sensitivity; 80%, specificity; 90% (PPV = 0.92 and NPP = 0.72). There was no difference between the diseased and normal side vessels diameter in patients with symmetric brain CT perfusion, however there was a difference in vessel diameter in patients with asymmetric brain CT perfusion (ICA; 1.7  $\pm$  0.5 vs 3.5  $\pm$  0.4, MCA; 2.1  $\pm$  0.8 vs 2.7  $\pm$  0.5, ACA; 1.5  $\pm$  0.6 vs 2.3  $\pm$  0.4, p < 0.05).

**Conclusion:** Signal intensity asymmetry of the head MRA by simple visualization or measurement predicts asymmetries of the brain CT perfusion in patients with CCD.

**14. Analysis of Cine MRI in Infectious Meningitis** Bijal Mehta, David Hojnacki, Eric Lindzen SUNY Buffalo, Buffalo, NY, United States

**Background:** Meningitis is associated with disruption of CSF flow particularly with decreased output across choroid plexus and upon return to the circulation across the arachnoid granulation tissue of the meninges. CINE MRI is used to determine changes in dynamics of CSF flow, specifically the CSF stroke volume across the cerebral aqueduct. Therefore, CINE MRI may be useful in determining changes in CSF flow dynamics in patients with forms of infectious meningitis.

**Methods:** Thirty patients will be apart of the study; ten patients with CSF confirmed viral meningitis and ten patients with CSF demonstrating bacterial meningitis. 10 non-meningitis

patients will be used as normal controls. CINE MRI will be performed at the time of suspected meningitis on those patients. CINE MRI will be done on 10 control patients as well. CSF stroke volumes across the cerebral aqueduct will be calculated from velocity sensitized phase maps acquired from the MRI imaging and using manufacturer provided software.

Values for normal CSF stroke volumes will be compared to those obtained from the patients in the study. Statistical analysis will be performed to determine if the differences in CSF dynamics is significantly different with comparison to normal controls and to previously published norms.

**Results:** We will demonstrate whether CINE MRI can detect a difference in CSF stroke volumes, and by inference CSF production in patients with meningitis compared to both our controls and published normal values in the literature.

**Conclusion:** CINE MRI may prove useful in diagnosis and prognosis of meningitis. It may provide a modality to track disease progression or improvement in patients with meningitis.

**15. Diffusion Weighted Imaging (DWI) and Arterial Spin Tagging (GREST) for Evaluation of Ischemic Stroke**

Eduardo Gonzalez-Toledo, Ajai Ravi, Maria Eugenia Gonzalez-Toledo, Mardjohan Hardjasudarma Louisiana State University Health Sciences Center, Shreveport, United States

**Introduction:** Comparison between infarct core and penumbra is the basis for treatment and prognosis in acute ischemic stroke. We propose two fast sequences: DWI to detect the infarct core and GREST to portrait penumbra.

**Patients (or Materials) and Methods:**

To 31 patients examined with a DWI sequence (10,000/135, b0/100) presenting with low ADC, a one slice arterial spin tagging sequence (GREST) was applied to the slice with largest diffusion abnormality. Perfusion images were processed to obtain color maps using MIPAV software (Medical Imaging Processing and Visualization,NIH). Follow up CT was obtained to assess final damage compared to diffusion/perfusion images.

**Results:** 18 patients presented with diffusion/ perfusion mismatch and 13 patients where diffusion and perfusion matched. The last ones showed permanent lesion in the area of matching diffusion/perfusion. Patients with mismatch evolved without a predictive pattern attributed to collateral circulation, arteries involved, time to treatment.

**Conclusion:** We propose the use of two

fast sequences (less than 10 minutes for both) to evaluate infarct core and penumbra, without use of contrast material and with a clear depiction of abnormalities, suitable for clinical use.

### **16. Syrinx Formation after Cervical Epidural Injection: A Case Report** Sara Khan, Joyce Lee, Erik Piro

Cleveland Clinic, Cleveland, OH, United States

**Introduction:** Cervical epidural injections are commonly used to treat chronic radicular neck pain. Several minor and major complications have been reported in literature. However syrinx formation, post cervical epidural injection, has not been described before.

**Patients and Methods:** A 52 year old female presented from an outside hospital after undergoing a cervical epidural injection. Under fluoroscopic guidance, an epidural needle was inserted at the C7-T1 level. Radiologic contrast showed appropriate epidural spread, after which preservative saline with triamcinolone was injected. Shortly after waking up from the procedure, the patient complained of inability to move her right arm and leg, numbness extending from the base of her neck to her right arm and leg, and urinary retention.

**Results:** MRI of the spine demonstrated a syrinx extending from the C1 to T4 level. There was no evidence of an epidural collection or blood. The patient was given high dose intravenous steroids with supportive management. Within a few hours she regained near normal strength of her right leg and over the course of the next 3 days, there was resolution of her sensory deficits with return of antigravity strength in her right arm.

**Conclusion:** Syrinx formation and focal myelomalacia following spinal anesthesia have been reported in the lumbar area, but there are no existing reports involving the cervical region. We present the first documented patient in this case report. It should be emphasized that spinal cord injury is a documented complication of spinal anesthesia at any level of the spinal cord, even with fluoroscopic guidance.

### **17. Metronidazole Toxicity Affects Structures of Guillain-Mollaret Triangle** Ahsan Moosa, Dwayne Perkins

Cleveland Clinic, Cleveland, Ohio, United States

**Introduction:** Metronidazole is a widely used drug with antibacterial and anti-protozoal activity. Long term treatment with metronidazole may result in sensory neuronopathy. Cerebellar ataxia due to metronidazole toxicity is less well known. We report a case of Metronidazole induced ataxia with characteristic MRI abnormalities.

**Patients (or Materials) and Methods:**

A 52-year-old man with remote post traumatic T7 paraplegia presented with acute onset dysarthria and arm ataxia, worsening over 1 week. He suffered from chronic osteomyelitis of right pelvic ischial bone requiring multiple courses of antibiotics and a recent regimen included Metronidazole. He had received a cumulative dose of 37.5 grams of Metronidazole over the preceding 5 weeks. Examination revealed dysarthria, prominent saccadic pursuit, gaze evoked nystagmus, upper limb dysmetria and T7 flaccid paraplegia.

**Results:** MRI of brain, axial T2 weighted and FLAIR images at the level of medulla and pons show symmetrical hyper-intensity over the inferior olivary nuclei, dorsal medulla, dentate nuclei, central tegmental tracts and the region around red nucleus bilaterally. DWI showed no diffusion restriction. These findings were typical of Metronidazole induced ataxia. Patient improved after cessation of Metronidazole. Follow up MRI showed complete resolution of MRI abnormalities.

**Conclusion:** Cerebellar toxicity is a rare complication of long term Metronidazole therapy. Radiological abnormalities suggest dentate nuclei involvement as the cause for ataxia. Our patient had signal abnormalities in other structures of Guillain-Mollaret triangle namely inferior olivary nucleus and the central tegmental tracts bilaterally. Clinical and radiological improvements occur with cessation of Metronidazole therapy.

### **18. Volume of Multiple Sclerosis Plaques: Correlation with the Extended Disability Status Scale (EDSS)** Eduardo Gonzalez-Toledo<sup>1</sup>, Bennett Hailey<sup>2</sup>, Alexis Thompson<sup>3</sup>, Mardjohan Hardjasudarma<sup>1</sup>

<sup>1</sup>Louisiana State University Health Sciences Center, Shreveport, LA, United States, <sup>2</sup>LSU College, Baton Rouge, LA, United States, <sup>3</sup>Bossier High, Bossier, LA, United States

**Introduction:** The Extended Disability Status Scale (EDSS) allows a person to be assigned a value from 0.0, fully ambulatory, to 10.0, death due to multiple sclerosis (MS). Although there has been controversy to the sensitivity of the EDSS with regards to impairments deviating from a patients gait, the scale has been shown to be both reliable and valid. Magnetic resonance shows different aspects of an MS plaque: T1WI detects mostly axonal loss, T2WI depicts edema and demyelination, T1WI+Gadolinium is positive for acute plaques. The purpose of this study was to look for a correlation between volumetric analysis of MS plaques and EDSS ratings

**Patients (or Materials) and Methods:** 17 patients with known MS were included in this retrospective study. Volumes for all plaques on

T2-weighted, enhancing post-contrast plaques, and demyelinated plaques on T1-weighted were then correlated to a patients EDSS rating in Microsoft Excel 2003.

**Results:** Although none of the three relationships were statistically significant, each one showed a positive relationship between the specific plaques and the patient's EDSS. Enhancing plaques on T1-weighted post-contrast images showed the most closely correlated relationship followed by demyelinated plaques in T1-weighted images and lastly, the sum of all the T2-weighted image plaques.

**Conclusion:** Plaque volumes on T2 and T1WI without and with contrast sequences can be correlated to the EDSS ratings of patients with MS although without statistical significance. This indicates that perhaps when reviewing radiological findings, volumes of plaques could be used as a marker for susceptibility to disabilities.

### **19. Reversal of Ventricular Asymmetry and Depression in Multiple Sclerosis (MS)** Eduardo Gonzalez-Toledo<sup>1</sup>, Bennett Hailey<sup>2</sup>, Alexis Thompson<sup>3</sup>, Mardjohan Hardjasudarma<sup>1</sup>

<sup>1</sup>Louisiana State University Health Sciences Center, Shreveport, LA, United States, <sup>2</sup>LSU College, Baton Rouge, LA, United States, <sup>3</sup>Bossier High, Bossier, LA, United States

**Introduction:** We previously found a correlation of reversal of ventricular asymmetry in patients with severe depression. Being depression a common finding in patients with multiple sclerosis we calculated an index of the ventricular volumes of right and left lateral ventricles and correlated with scores in Beck Depression Inventory (BDI).

**Patients (or Materials) and Methods:** Axial T2-weighted and T1-weighted pre and post contrast MR images were examined from 44 MS patients. A volumetric analysis of the lateral ventricles from the most recent MR scans was performed (MIPAV,NIH). A correlation was made between the ventricular ratios and the 21 components as well as the total score on the BDI. The correlations were then analyzed for statistical significance.

**Results:** Of the 44 patients who were surveyed 22 responded the BDI questionnaire. The correlation of ventricular ratios and overall BDI score showed a positive relationship between the two. Only one of the components of the BDI was significantly correlated to ventricular ratio, loss of pleasure.

**Conclusion:** Depression scaled by the BDI can be correlated to reversal of brain asymmetry in the ventricular ratios with approaching significance. Of the 21 components of the BDI, only loss of pleasure was significantly correlated to the ventricular ratios.

Although a significant relationship does not exist between depression and reversal of brain asymmetry, a dilated ventricle in the dominant hemisphere giving a ratio indicating reversal of asymmetry may be used as a sign of increasing susceptibility to depression in MS patients.

## **20. Altered Intra and Inter Hemispheric Fiber Connection in Agnesis of the Corpus callosum: A Case Report** Juebin Huang<sup>1</sup>, Robert P. Friedland<sup>2</sup>, Jean Tkach<sup>3</sup>, Alexander P. Auchus<sup>1</sup>

<sup>1</sup>Department of Neurology, University of Tennessee Health Science Center; Neurology and Research Services, Memphis VAMC, Memphis, TN, United States, <sup>2</sup>Department of Neurology and Radiology, University Hospitals-Case Medical Center, Cleveland, OH, United States, <sup>3</sup>Department of Radiology, University Hospitals-Case Medical Center, Cleveland, OH, United States

**Introduction:** Agnesis of the corpus callosum (ACC) is a rare developmental abnormality in which cerebral association fibers fail to decussate to the contralateral hemisphere. We describe an ACC patient with altered intra- and inter-hemispheric white matter fiber connections revealed by diffusion tensor imaging (DTI).

**Patients and Methods:** A 22 year-old woman presented with mental retardation, epilepsy and behavioral abnormalities. Conventional brain MRI displayed complete absence of the corpus callosum, as well as small lateral ventricles. DTI map calculation and fiber tractography (FT) were performed using DTI Studio. For comparison, DTI data from a 35 year-old normal control subject were obtained and analyzed using the same protocols.

**Results:** In the ACC patient, DTI color maps and three dimensional FT showed a thick fiber bundle running anteroposteriorly, located medial to the lateral ventricles, representing the Probst bundle. FT of the normal subject with regions of interest positioned at similar locations displayed fiber bundles appropriately crossing the midline. FT revealed the anterior commissure to be more prominent in the patient than the normal control, with average FA = 0.42 in patient vs. 0.28 in control. Moreover, the transverse pontine fiber volume was increased in the patient as compared to the control, with average FA = 0.53 in patient vs. 0.33 in control. These fibers contribute to the middle cerebellar peduncles and then distributed to the cortex of the cerebral hemispheres.

**Conclusion:** In ACC, DTI with FT revealed altered white matter fiber connections including increases in secondary commissural pathways.

## **21. Osmotic Balance: Brain MRI in**

## **Central Pontine and Extrapontine Myelinolysis** Elizabeth Hartman, Steven Shook Cleveland Clinic, Cleveland, Ohio, United States

**Introduction:** Central pontine myelinolysis (CPM) and extrapontine myelinolysis (EPM) are rare, but serious, complications resulting from shifts in the delicate cerebral osmotic balance. The result is non-inflammatory demyelination within the pons and extra-pontine sites causing devastating neurological injury.

**Patients (or Materials) and Methods:** A case-study with timetable of symptoms, Brain MRI and outcome is presented. Pertinent literature review will also be summarized.

**Results:** A 42 year old woman was found down in her home with altered mental status. Her history revealed alcohol dependence and cirrhosis. On admission, she was noted to have slurred but intact speech and was otherwise without neurological deficits. Initial serum sodium level was 118. Patient was treated with intravenous normal saline. Serum sodium level was corrected as follows: Presentation-118, day 1-125, day 2-141, day 4-134, day 8- 133, day 14- 150. On day 13 post-presentation, patient was noted to develop right facial droop. On day 14, tetraparesis was observed.

CPM was suspected due to clinical history and examination findings. Brain MRI was performed with and without gadolinium contrast and revealed restricted diffusion involving the pons, posterior limb of internal capsules, cerebral peduncles and patchy involvement of the splenium of the corpus callosum. Additional subtle restricted diffusion and FLAIR hyperintensity was noted within bilateral thalami. Mild diffuse enhancement of the pons was noted on post-contrast imaging.

**Conclusion:** CPM/EPM are devastating consequences of rapid correction of chronic hyponatremia. MRI imaging findings may occur early or late in the clinical course. MRI findings may correlate with severity of injury and patient outcome.

## **22. Intracranial Aneurysm Mimicking Neoplasm on MR** Ehsan Malek, Jamshid Ahmadi, Nerses Sanossian University of Southern California, Los Angeles, United States

**Introduction:** There are limitations of MRI/MRA in establishing diagnosis in certain situations. We report two cases of intracranial aneurysm initially misdiagnosed as neoplasm to highlight some pitfalls.

**Patients (or Materials) and Methods:** Review of case records, and relevant neuroimaging.

**Results:** The two patients presented with acute third nerve palsy. The first

patient was noted to have a sellar/suprasellar mass on CT. The imaging characteristics and evaluation led to a diagnosis of pituitary adenoma. Definitive diagnosis was made during trans-sphenoidal surgery for the presumed pituitary adenoma. The second case was diagnosed as a meningioma due to the finding of a solid enhancing lesion on MRI with no flow signal on MRA. Definitive diagnosis was made during catheter angiography, which showed a very narrow neck aneurysm with stagnant blood flow inside. Both of these cases were eventually diagnosed as posterior communicating artery (PCOM) aneurysm (6 mm & 8 mm).

**Conclusion:** Awareness of the various imaging characteristics of intracranial aneurysm is very important. These cases demonstrate the need to consider aneurysms among masses found at the base of the brain. Identifying conditions which have these types of MR signal characteristics is important in planning appropriate treatment and avoiding tragic consequences.

## **23. Imaging of Basal Ganglia Lesions in Hyperglycemia Induced Hemiballismus** Zuheir Alkawi

KFSH&RC, RIYADH, Saudi Arabia

**Introduction:** Hemiballismus is a rare complication associated with hyperglycemia. It is also associated with distinct unusual imaging features.

**Patients (or Materials) and Methods:** A young diabetic presenting with left hemiballismus had brain imaging studies including CT, MRI, MRA and PET.

**Results:** The patient had high serum glucose (23.4 mmol/L) high hemoglobinA1c (0.161 Fraction) High osmolarity (302 mOsm/kg) and negative ketones in blood and urine. Brain CT showed hyperdense lesion in the right striatum. High T1 signal was present in the caudate and putamen bilaterally right greater than left and was associated with lack of susceptibility on T2\* images. No diffusion abnormalities were noted early in the course of illness but some T2 changes and minimal diffusion abnormalities appeared on 14 days follow up. There was absent FDG metabolism in the right striatum on PET scan. The patient improved slowly after control of hyperglycemia and treatment with tetrabenazine, valproate and clonazepam.

**Conclusion:** Rare and peculiar imaging features are seen in hemiballismus syndrome associated with non-ketotic hyperglycemia. The pathology of these changes is debatable.

## **24. Low Grade Astrocytoma Masquerading as an Atypical Case of Multiple Sclerosis** Kamaldeen Saldin, David Hojnacki

State University of Buffalo, Buffalo, NY, United States

**Introduction:** Multiple sclerosis (MS) is the most common cause of disability in young adults. Atypical MS lesions can be seen but meticulous imaging and close follow-up are needed to help differentiate MS from other etiologies.

**Patients (or Materials) and Methods:** We describe a case report of a 47 year old woman with a 4 year history of left arm weakness was referred to our center in 1994 for suspected multiple sclerosis. She had new onset left leg weakness at that time. Neurological examination revealed mild left sided weakness with upper motor neuron signs. MRI of the brain demonstrated a large right fronto-parietal T2 hyperintense lesion without edema or mass effect. There was a second, similar, T2 hyperintense lesion adjacent to the posterior horn of the left lateral ventricle. No contrast enhancement was seen. Extensive laboratory and spinal fluid analysis was unremarkable. Repeat imaging was performed at frequent intervals for 12 years without any change. She recently developed worsening left side weakness, stiffness and difficulty with gait. Repeat MRI of the brain revealed significant interval changes including, a contrast enhancing mass lesion in the WM of the right frontal lobe that extended into the corpus callosum. Axial FLAIR imaging revealed extensive white matter edema surrounding the enhancing lesion.

**Results:** Stereotactic biopsy revealed a WHO Grade 3 Astrocytoma.

**Conclusion:** Our case highlights the fact that a low-grade astrocytoma could mimic an atypical MS lesion and close monitoring is required for an early diagnosis.

### 25. Septo-optic Dysplasia Complicated by Infantile Spasms and Bilateral Choroidal Fissure Arachnoid Cysts

Emir Tas, Molly Tracy, Dean Sarco, Yaman Eksioğlu, Tobias Loddenkemper

Department of Neurology, Division of Epilepsy and Clinical Neurophysiology, Children's Hospital Boston, Boston, MA, United States

**Introduction:** Septo-optic dysplasia (SOD) presents with the triad of optic nerve hypoplasia, panhypopituitarism and agenesis of septum pellucidum. SOD is described along with infantile spasms, periventricular nodular heterotopias and midline interhemispheric cyst in one previous case.

**Methods:** We report a patient with global developmental delay, SOD, panhypopituitarism, ventriculomegaly status post ventriculoperitoneal shunt placement, infantile spasms, bilateral choroidal fissure cysts at the base of the brain and cortical dysplasia. Additionally, we reviewed the literature for cases with SOD, arachnoid cyst and infantile spasms.

**Results:** A 4 year-old girl presented with hypothermia and hypoglycemia shortly after an uncomplicated pregnancy and delivery. Within a few days of birth a fixed and dilated right pupil was noticed. CT revealed bilateral ventriculomegaly and bilateral choroidal cysts. She then developed seizures and was diagnosed with infantile spasms which responded to ACTH. MRI revealed absence of the septum pellucidum and optic nerve hypoplasia. Additionally, bilateral choroidal cysts at the base of brain in close relationship to the brain stem and frontal lobe pachygyria with heterotopic gray matter were noted. Despite cyst fenestration, follow up MRI showed persistency of that cyst.

**Conclusion:** We found one previous case of co-incident infantile spasms, SOD and interhemispheric arachnoid cyst. No previous cases with bilateral choroid fissure cysts have been described. It is unclear whether presence of bilateral cysts presents a new syndrome or a SOD spectrum variation. Patients with SOD and arachnoid cysts should be monitored for signs of herniation.

### 26. Transverse and Sigmoid Venous Sinus Thrombosis in a Child with Mastoiditis and Thrombocytosis

Partha Ghosh, Amaran Moodley, Johanna Goldfarb, Debabrata Ghosh  
Cleveland Clinic, Cleveland, United States

**Introduction:** Cerebral Venous Sinus Thrombosis (CVST) is an infrequent complication of otitis media in the antibiotic era.

**Patients (or Materials) and Methods:** We report a child with bilateral otitis media, right mastoiditis complicated by transverse and sigmoid sinus thrombosis, elevated intracranial pressure (ICP) and thrombocytosis.

**Results:** A previously healthy 6 year old male presented with diplopia and headache following treatment of bilateral acute otitis media. On examination there was right middle ear effusion, bilateral papilledema, left 6<sup>th</sup> and 7<sup>th</sup> cranial nerve palsies. He had thrombocytosis (platelet count 661 k/uL). MRI brain and MRV showed thrombosis of right transverse and sigmoid venous sinuses without brain parenchymal changes. Both mastoid air cells and middle ear cavities had fluids. Bilateral tympanostomy tube insertion and a four week course of intravenous ceftriaxone resolved the symptoms. MRI after 4 months showed recanalization of the dural venous sinuses and resolution of mastoid and middle ear pathology. He received subcutaneous Low Molecular Weight Heparin for 4 months, stopped after repeat MRI. His platelets normalized in 1 month following treatment.

**Conclusion:** There should be a high

degree of suspicion for CVST in a setting of mastoiditis and otitis media presenting with headache and focal neurological deficits. Development of diffuse raised ICP due to unilateral lateral sinus thrombosis is explained by the fact that superior sagittal sinus drains the majority of both hemispheres before draining to one lateral sinus; usually there is no true confluence of sinuses. Transient thrombocytosis as a nonspecific inflammatory response may contribute to development of CVST.

### 27. Ruptured Intrathecal Epidermoid Cyst with Secondary Meningitis and Hydrocephalus: A Clinicopathologic Study

Mikayel Grigoryan, William Andrews, Tanya Harlow  
Department of Neurology, University of Iowa Hospitals and Clinics, Iowa City, IA, United States

**Introduction:** Spinal epidermoid cysts are very rare and typically appear isointense to CSF on T1 and markedly hyperintense on T2-weighted images on MRI. We report a case of biopsy-proven ruptured giant epidermoid cyst of the lumbosacral spine complicated by meningitis and hydrocephalus with unusual MRI characteristics.

**Methods:** Case Report

**Results:** A 52 year-old woman was admitted for renal failure. Abdominal CT suggested a spinal lesion and MRI of the lumbar spine revealed an expansile intrathecal mass extending from the tip of the conus medullaris to approximately L2 level showing high intensity on T1, heterogeneously low on T2 and predominantly high on STIR. It was read as a myxopapillary ependymoma and surgery was deferred until medically stable. Her neurological exam was then significant only for a left upgoing toe. Three days later, she developed rapidly progressive leg weakness and lethargy. On reassessment, she was comatose with intermittent jerking of both arms and head, had no response to noxious stimuli and absent reflexes in the lower extremities. Brain imaging revealed meningitis and ventriculitis with hydrocephalus. Repeat spine MRI showed extension of the mass to T11 with heterogeneous contrast enhancement and enhancement of subarachnoid space. She underwent ventriculostomy and mass aspiration. Pathology revealed fibrinopurulent exudate with acute inflammation consistent with a ruptured infected epidermoid cyst. Despite aggressive treatment, she expired in 22 days.

**Conclusions:** Epidermoid cysts may present with unusual MR characteristics that could be explained by their high protein content and viscosity. Ruptured spinal epidermoid cysts may lead to serious neurologic complications.

## 28. MRI Findings in Adult Hemispherectomy Patients with Post-traumatic Epilepsy and Previous Epilepsy Surgery

Ngoc Minh Le<sup>1</sup>, Tobias Loddenkemper<sup>2</sup>, Andreas Alexopoulos<sup>1</sup>, Lara Jehli<sup>1</sup>, William Bingaman<sup>1</sup>

<sup>1</sup>Cleveland Clinic, Cleveland, OH, United States, <sup>2</sup>Children's Hospital Boston, Boston, OH, United States

**Introduction:** Hemispherectomy is a treatment option in selected adults with intractable seizures. We describe two adults with intractable post-traumatic epilepsy that required hemispherectomy after resective surgery failed to control seizures.

**Patients:** A 22 year-old woman had seizures since 3 years-old after head trauma. Initial brain MRI was interpreted as normal. She underwent right temporo-parieto-occipital resection at 15 years based on non-invasive EEG findings. Habitual seizures remained intractable. MRI 2.5 years post-op showed diffuse volume loss, extensive encephalomalacia, and subcortical gliosis involving both frontal poles, parietal lobes, and right temporal lobe. Right functional hemispherectomy was performed at 18 years. Seizure reduction was greater than 99% (<1 per month); one of three antiepileptic drug (AED) was discontinued at 56-months post-op. A 35 year-old man had a generalized motor seizure at 6 weeks-old secondary to right post-traumatic parietal hemorrhage with emergent centroparietal resection. He had no further seizures on Phenobarbital for the first 9 months. A new seizure type developed after viral meningitis at 5 years. They consisted of staring and right hand automatisms, and were initially controlled with AEDs. At 28 years, seizure frequency increased. MRI showed right mesial temporal sclerosis, encephalomalacia, and volume loss throughout right hemisphere. Right functional hemispherectomy was performed. Complete seizure freedom and discontinuation of two of three AEDs were achieved at 46-month follow-up.

**Conclusion:** Hemispherectomy should be considered in carefully selected adults with early-onset intractable seizures, previous partial resection, and history of hemispheric insult. Epileptogenic zone due to head trauma may be larger than suggested by initial presurgical investigations.

## 29. A Case Report of Mistreating the Headache: 34 Year Old Male given Multiple Analgesics for Months before Diagnosis Revealed by MRI

Edward Tay, Kamal Chemali  
Cleveland Clinic, Cleveland, OH, United States

**Introduction:** Spontaneous intracranial hypotension is caused by leakage of CSF with resultant CSF hypovolemia

and intracranial hypotension. It often occurs in the absence of any identifiable initiating event. Diagnosis can be reached by a combination of imaging studies which may include MRI with gadolinium, nuclear cisternography and myelography. We describe a case report of spontaneous intracranial hypotension and the characteristic MRI findings corresponding to the diagnosis and subsequent treatment.

### Patients (or Materials) and

**Methods/Results:** 34 year old male who initially presented with chronic daily headache for 2 months. The headache had a postural component to it and was associated with tinnitus, photophobia, and nausea and vomiting. Initial CT brain was normal. His neurological exam was normal. He was treated for 2 months with multiple narcotics, triptans, and NSAIDs with no relief. His clinical history led us to do a MRI brain which revealed the diagnosis. We reviewed the literature on clinical and neuroimaging findings of spontaneous intracranial hypotension and latest treatment.

**Results:** MRI brain with gadolinium revealed pachymeningeal enhancement, caudal brain "sag," and secondary bilateral subdural hematomas. MRI findings were pathognomic of spontaneous intracranial hypotension. MRI spine did not help us localize the leak nor CT myelography. **Conclusion:** Intracranial hypotension has characteristic imaging findings which include brain "sag", linear enhancement of the pachymeninges and subdural effusions. MRI findings can be normal in 21–32% of patients but usually yields the diagnosis. Neuroimaging is used extensively in the diagnosis and treatment of spontaneous intracranial hypotension.

## 30. Neuroimaging of Gliomatosis

Cerebri Majid Molaie

Little Company of Mary, San Pedro, CA, United States

This is a case report of a 51-year-old previously healthy man with rapidly progressive neurological deficits in period of two months. Multiple MRIs of brain during the course of his disease revealed numerous non-enhancing lesions, best observed in FLAIR and DWI sequences, predominantly in white matter of cerebral hemispheres, brainstem and cerebellum. Biopsy from one of the lesion in the right frontal area revealed non-specific inflammatory process. He was treated with several courses of immune-modulatory drugs on assumptive diagnosis of acute disseminated encephalomyelitis with dismal response and further neurological deterioration and death. Brain autopsy revealed gliomatosis cerebri (GC).

Discussion of the case will be focused on differential diagnosis of neuro-imaging of GC that may guide us for accurate

diagnosis of this rare malignancy.

## 31. A Case of Pituitary Apoplexy Presenting as Isolated Sixth Cranial Nerve Palsy

Hyun-Jung Kim, M.D., Hee-Kwon Park, M.D., Jae-Kyu Roh, MD., Ph.D.

Department of Neurology, Seoul National University Hospital, Seoul, Korea

**Background:** Pituitary apoplexy (PA), a serious complication of pituitary adenoma, is characterized by abrupt onset of headache, nausea, vomiting, visual disturbances and oculomotor paresis. Visual field defects are the most frequent ophthalmic manifestation of pituitary tumors. However, isolated sixth nerve palsy, sparing the visual field, is a rare presenting sign of PA. We report an unusual case of a patient with pituitary adenoma who initially presented with isolated sixth nerve palsy in the setting of apoplexy.

**Case Presentation:** An 80-year-old man complained of severe headache and diplopia. The initial evaluation indicated isolated sixth nerve palsy of the right eye, without visual field defect, and anhidrosis of the right forehead. Brain MRI demonstrated that the pituitary hemorrhage from pituitary adenoma had a sedimentation level within the pituitary fossa, involving the right cavernous sinus. Several days after glucocorticoid therapy, the patient's diplopia did not improve, and he developed hyponatremia with episodes of dizziness. The patient refused surgical treatment, but was treated medically with intravenous glucocorticoid replacement and correction of electrolyte imbalance. His clinical symptom recovered gradually: headache for a few days, anhidrosis over two weeks and diplopia over two months. One month after the ictus, steroid was tapered off according to the normal hormonal levels. He is quite normal except some dizziness which had been before the apoplectic episode. **Conclusions:** We suggest that pituitary apoplexy should be included as a rare differential diagnosis in a case with sudden onset headache and isolated sixth nerve palsy.

## 32. A Case of Atypical Multi-Focal CNS Lesions: When to Test and When to Treat?

Eric Baron, Robert Fox

Cleveland Clinic Neurological Institute, Cleveland, OH, United States

**Introduction:** Atypical neuroimaging leads to diagnostic uncertainty, often delaying initial therapy during evaluation. This case illustrates the challenges inherent in patients who present with multi-focal CNS lesions. **Patients (or Materials) and Methods:** A 20-year-old female developed urinary urgency and pain below her abdomen after a camping trip. Symptoms progressed over 10 days to paraplegia,

lower extremity paresthesias, urinary retention, dysarthria, dysphagia, headache, blurred vision and autonomic dysfunction (bradycardia, orthostatic hypotension).

**Results:** MRI showed multiple, non-enhancing T2/FLAIR hyperintensities with minimal edema involving both hemispheres, brainstem and spinal cord from C5 to conus medullaris. Because of possible infection, lymphoma or other neoplasia, steroid treatment was delayed until test results were obtained. CSF showed WBC 470 (46% neut), RBC 21, protein 64, glucose 55, no oligoclonal bands, myelin basic protein 36.5, kappa chains 0.7, IgG synthesis/index 11.8/0.68, negative cytology and flow cytometry. Viral, fungal and bacterial evaluations were negative except serum Mycoplasma IgG 2.50. Neuromyelitis optica (NMO) IgG, visual evoked potentials and ophthalmology exams were unremarkable. Eventually, acute disseminated encephalomyelitis (ADEM), seronegative NMO and fulminant multiple sclerosis were the remaining diagnostic possibilities and high dose corticosteroids initiated, followed by five plasma exchanges. Six weeks later, she was ambulatory with mild gait ataxia and persisting neurogenic bladder. Brain imaging showed marked improvement with no new lesions.

**Conclusion:** CNS demyelination often has atypical presentations on neuroimaging, leading to diagnostic uncertainty and delay in treatment. Rapid evaluation for etiologies in which steroids could be harmful is crucial for early steroid initiation and optimal neurologic recovery.

### 33. MRI Abnormalities in Cervical Spines of Young Physicians Sandeep

Rana, Arash Taavoni  
Allegheny General Hospital, Pittsburgh, PA, United States

**Introduction:** It is known that Occupational stress can lead to accelerated spinal degeneration. Surgeons using microscope for extended periods during surgery and physicians doing procedures wearing protective lead gowns are putting considerable strain on the neck. We report three young physicians who presented with acute neck pain and radicular symptoms. The MRI scans revealed advanced cervical spondylosis for age.

**Patients (or Materials) and Methods:** Case I: 45 year-old Ophthalmologist presented with history of long-standing neck pain and acute onset of weakness in hands after she had performed microscopic ophthalmic surgery for extended period of time.

Case II: 39 year-old Gastroenterologist presented with pain down his right arm and weakness of hand particularly after he would spend long hours in the

endoscopy unit wearing heavy lead jacket around his neck.

Case III: 38 year-old Cardiologist presented with sudden onset of neck pain during a golf swing. He admitted he would get intermittent neck pain when he would perform cardiac catheterization wearing lead jacket around neck.

**Results:** All three cases had MRI of cervical spine, which revealed multiple level degenerative changes.

**Conclusion:** Advances in medical technology such as microscopic surgery, endoscopic procedures and catheterization are putting increased physical demands on physicians. We present 3 MRI studies showing early cervical spondylosis in physicians, the underlying pathophysiology of which is probably physical stress of performing medical procedures. Ergonomic studies to lessen physical strain on Physicians are warranted.

### 34. Extensive Infantile Hemangioma with Spinal

**Involvement: A Case Report** Ninon Pachikara, Debabrata Ghosh, Neil Friedman  
Cleveland Clinic Foundation, Cleveland, OH, United States

**Background and Purpose:** Hemangiomas are the most common vascular tumors of infants. The natural history typically follows a benign, self limited course. However, its complications can cause major deformities and affect vital organs. We present a 6 week old infant girl with multiple cutaneous and extensive visceral, extra pleural, paraspinal and spinal hemangiomas.

**Methods:** Details of history, examination, investigation and management of a single case was recorded and being presented.

**Results:** A 6 week old Caucasian baby girl presented with multiple cutaneous hemangiomas of the head, face, neck, back, right leg and buttock. There was no family history of similar lesion. The neurological examination showed mild hypotonia with brisk symmetrical reflexes of the lower extremities. There was no evidence of hyperdynamic circulation. General physical and other systemic examinations were normal. Echocardiography revealed a ventricular septal defect. Ultrasound followed by CT scan examination showed extensive hemangiomatous lesions in the liver, extrapleural and oropharyngeal areas. MRI brain and spine showed bilateral paraspinal hemangiomas with large intraspinal T5-T9 level extradural lesion producing cord compression. Cerebral and spinal MR Angiogram did not demonstrate any evidence of arteriovenous malformation. There was no evidence of consumptive coagulopathy or thrombocytopenia. The child was started on methylprednisolone at 4 mg

every 6 hours. Repeat MRI spine in 1 week showed a significant reduction in lesion size.

**Conclusion:** Extensive cutaneous hemangiomas in association with intraspinal involvement is very rare. A knowledge of such occurrence, appropriate investigation and early diagnosis with prompt treatment may prevent serious neurological complications.

### 35. Moderate Correlation between Two Methods of Transcranial Doppler Cerebral Vasomotor Reactivity Testing Abiezer

Rodriguez, Sebastian Koch, Iszet Campo-Bustillo, Jose Romano  
University of Miami, Miami, FL, United States

**Introduction:** Diminished cerebral vasomotor reactivity is associated with increased stroke risk. Vasomotor reactivity is assessed with transcranial Doppler (TCD) using a variety of vasoactive stimuli. However, there has been little comparison between different techniques. We here examine the correlation of breath holding index (BHI) and hypercapnia/hypocapnia induced by administering CO<sub>2</sub> and hyperventilation.

**Methods:** Cerebral vasomotor reactivity was tested by both BHI and induced hypercapnia (5% CO<sub>2</sub> gas mixture inhalation) and hyperventilation in 66 consecutive patients. BHI was calculated as the percent increase in middle cerebral artery flow velocity divided by time of breath holding. An average of 2 trials was obtained. The percent increase in middle cerebral artery flow velocity from hyperventilation to hypercapnia was calculated for the 5% CO<sub>2</sub>/hyperventilation method. A BHI of < 0.69 and reactivity of < 70% for the 5% CO<sub>2</sub>/hyperventilation were classified as impaired. We compared the correlation of detecting impaired vasoreactivity between the 2 methods. **Results:** We enrolled 66 patients with 132 arteries available for analysis. BHI classified 57/132 arteries with impaired reactivity. The 5%CO<sub>2</sub> hyperventilation method identified 89/132 arteries as impaired. The correlation for the right and left middle cerebral artery were r = 0.4 (p = 0.001) and r = 0.3 (p = 0.009) respectively.

**Conclusion:** Vasoreactivity to CO<sub>2</sub> as examined by 2 different techniques yielded only moderate correlation. The factors affecting the moderate correlation are not fully understood, and require further study.

### 36. Neurosonographic Diagnosis of Neonatal and Infantile Dural Sinus Thrombosis Paul Maertens, April Ross, Lee Vick, Zayek Michael, Eyal

Fabian, Hamm Charles, Whitehurst Richard, Vidal Rosa, Falkos Sheryl, Koper-Skladanic Izabela  
University of South Alabama, Mobile, AL, United States

**Introduction:** Dural sinus thrombosis (DST) is thought to be rare in neonates and young infants but it is feared for its devastating consequences. An understanding of the natural history of asymptomatic DST is important for rational application of new interventions. Up to date, there are no prospective studies of the incidence and outcome of DST.

**Patients and Methods:** Power Doppler imaging through the anterior and posterior fontanelles was used to screen for DST in all sick neonates and infants admitted between January 2005 and present (850 patients).

**Results:** DST was identified in 3 neonates and 4 infants. Two neonates were born to mothers treated with enoxaparin for autoimmune hypercoagulable state. Both infants suffered from a severe hemorrhagic encephalopathy due to sagittal sinus thrombosis in one and sigmoid sinus thrombosis in the other one. The other neonate had perinatal asphyxia and was treated with hypothermia therapy. A partial sagittal sinus thrombosis was diagnosed and resulted in a less extensive encephalopathy. Two infants with bacterial meningitis and seizures were diagnosed with sagittal sinus thrombosis and diffuse encephalopathy. One infant with acute ischemic encephalopathy had a severe hemorrhagic encephalopathy due to complete sagittal sinus thrombosis. Another infant with partial sagittal sinus thrombosis during a febrile illness made a complete recovery

**Conclusion:** Power Doppler imaging may be used for screening and follow-up of DST in high risk neonates and infants. DST is not as rare as previously thought. The outcome is poor in all cases when thrombosis is complete. Partial thrombosis is associated with a better outcome and spontaneous recanalization.

### **37. Antibodies to Chlamydia Pneumoniae are Associated with Increased Carotid Artery Intima-Media Thickness in Asymptomatic Indian**

**Individuals** Subhash Kaul, Bandaru VCSS, Laxmi V, Neeraja M, Umamahesh MC, Suvarna Alladi  
Nizam's Institute of Medical Sciences, Hyderabad, (AP), India

**Introduction:** Chlamydia pneumoniae infection (*C. pneumoniae*) has been found associated with cerebrovascular and cardiovascular diseases in seroepidemiological studies. The aim of this study was to investigate whether this organism is associated with increased intima-media thickness (IMT) of common carotid arteries in

asymptomatic individuals from the south Indian city of Hyderabad

### **Patients (or Materials) and Methods:**

Serum titer of antibodies to *C. pneumoniae* (IgA and IgG) in 100, consecutive asymptomatic subjects above 40 years were measured by microimmunofluorescence. These subjects also had their IMT measured by B-mode ultrasound in the common carotid artery (CCA) on both sides.

**Results:** Comparison of baseline characteristics between the group with abnormal IMT ( $>0.08$  cm) and group having normal IMT ( $\leq 0.08$  cm) showed significant association of *C. pneumoniae*

antibodies and hypertension with former. Multiple logistic regression (Stepwise method), established *C. pneumoniae* as an independent risk factor for increased IMT.

**Conclusion:** This study has demonstrated that the evidence of *C. pneumoniae* infection is associated with an increase of IMT in the common carotid artery among asymptomatic individuals from the south Indian city of Hyderabad.

### **38. Diagnostic Criteria for Detection of Intracranial Arterial Stenosis by Transcranial Doppler in Comparison with Magnetic Resonance Angiography; "A Validation Study from Nizam's Institute Stroke Registry, Hyderabad, India (NISHI)"**

Subhash Kaul, Demudu Babu, Suvarna Alladi, Jyotsna Y, Padmaja D, VCSS Bandaru  
Nizam's Institute of Medical Sciences, Hyderabad, (AP), India

**Introduction:** Patients with  $\geq 50\%$  narrowing of intracranial arteries may require more intensive treatment in acute ischemic stroke. This study was aimed to determine accuracy of Transcranial Doppler (TCD) in comparison to Magnetic Resonance Angiography (MRA) in detecting intracranial arterial stenosis in patients with acute cerebral ischemia and to establish diagnostic criteria based on velocities to detect various degrees of intracranial arterial stenosis.

### **Patients (or Materials) and Methods:**

Both TCD and MRA examinations were performed on 150 patients with acute cerebral ischemia. The peak flow velocities of intracranial vessels were recorded. Severity of Middle cerebral artery (MCA) stenosis on MRA was classified as normal-mild ( $<50\%$  lumen diameter reduction), moderate ( $50\%-75\%$ ), and severe ( $>75\%$  to void of flow signal). Severity of other intracranial vessels was classified as normal –  $<50\%$  and  $>50\%$  stenosis on MRA.

**Results:** The optimal cutoff velocity for detection of MCA  $>50\%$  stenosis was found at peak systolic velocity  $>140$  cm/s and for  $>75\%$  stenosis was  $>180$

cm/s on TCD. The cutoff TCD velocity for  $>50\%$  stenosis of Anterior cerebral artery (ACA) and Internal carotid artery (ICA) was  $>120$  cm/s, while for Posterior cerebral artery (PCA), Vertebral artery (VA) and Basilar artery (BA) it was  $>100$  cm/s.

**Conclusion:** Despite a relatively high percentage (14.67%) of technically impossible exams in this series, TCD enables grading of the severity of intra cranial vascular (MCA, ACA, PCA, VA, BA, ICA) stenosis according to the flow velocity. TCD is proposed as a reliable tool for immediate and sequential monitoring of intracranial stenosis.

### **39. TCD and TCD with Agitated Saline – Clinical Results over 4 Years**

Thomas Alexander, Lester Collins, Preston Harrison  
1Southwestern Cerebral Circulatory Dynamics, Tyler, TX, United States, 2East Texas Neurological Institute, Tyler, TX, United States  
From mid-2004 to mid-2008; 292 patients ranging in age from (23–86) with 1 or more MRI confirmed areas of infarct; had a complete TCD exam followed by agitated saline injections with a timed and gauged Valsalva maneuver. 56 (19%) had TCD confirmed large right-to-left cardiac shunts with greater than 25 microembolic signals (MES) passing through the left MCA. 17 (6%) had 10–25 MES. 35 (12%) had 1–10 MES. Of the 292 stroke patients without any cardiac shunting; 42 (14%) had TCD mean velocities of greater than 90 cm/sec in one or more arteries. TCD added diagnostically relevant physiologic information in 37% of this group. A parallel group of 177 patients (ages 15–86) without MRI confirmable evidence of stroke but with clinically diagnosed TIA's that effected vision had the same TCD tests performed. 15 (8%) had greater than 25 MES, 6 (3%) had 10–25 MES, and 21 (12%) had 1–10 MES. 13 (7%) had TCD mean flow velocities of greater than 90 cm/sec in one or more arteries. TCD added diagnostically relevant physiologic information in 31% of this group.  
**Conclusion:** Although therapeutic options on these classifications of patients are many with some being controversial; TCD remains a cost-effective; non-toxic, bedside tool to gather clinically relevant information about stroke and TIA patients unobtainable by any other methods or techniques.

#### **40. Ultrasonographic Diagnosis of Posterior Fossa Dermoid Cyst**

Ross, Paul Maertens, Sushma Gupta, Lee Vick

University of South Alabama, Mobile, Alabama, United States

**Introduction:** Dermoid cysts (DC) are frequently associated with other congenital abnormalities and are usually sporadic. Ultrasonographic features of posterior fossa DC have not been reported.

#### **Patients (or Materials) and Methods:**

A term neonate treated at birth for group B streptococcal pneumonia and sepsis undergoes a neuronosonographic evaluation through the posterior fontanelle on day of life 13 after being suspected on MRI of the brain to have a straight sinus thrombosis. The MRI of brain shows an elongated mass with increased signal intensity on T1 and low signal intensity with T2-weighted images.

**Results:** Power Doppler of the straight sinus and vein of Galen is normal. Through posterior fontanelle, a well circumscribed mass is seen with a 7.5 MHz transducer. In the sagittal plane, a midline elongated (1.1 cm long) echogenic mass with anechoic center is seen above the cerebellum and below the tentorium. The mass displaces slightly the straight sinus. In the coronal plane the mass is 0.5 cm high and 0.8 cm wide. MRA confirms the diagnosis of DC showing patency of the sinuses and enhancement of the cyst.

**Conclusion:** Posterior fossa DC appears anechoic with an echogenic rim on ultrasound. It should be differentiated from posterior fossa lipoma which is hyperechogenic.

#### **41. Cervical Hematomyelia as a Complication of a Trigger Point Injection**

Bhavik Gedia, Sandeep Rana Allegheny General Hospital, Pittsburgh, PA, United States

**Introduction:** There have been reports of iatrogenic epidural hematomas following lumbar puncture, epidural steroid injections or anesthesia. We present a case of cervical hematomyelia following an attempted trigger point injection.

#### **Patients (or Materials) and Methods:**

28-year-old female with refractory pain was treated with trigger point injection by a general practitioner. With the injection, patient immediately complained of neck pain and became weak in her right arm.

**Results:** She was initially treated symptomatically but when her symptoms persisted, she presented to emergency room where MRI revealed cervical cord hematoma from C2 to C6 level. This location did correspond to her site of trigger point injection. She did not have history of bleeding diathesis and she was not on anticoagulants. She was evaluated by Neurosurgery and treated

conservatively.

**Conclusion:** Our case underscores the risk of spinal hematomas, i.e. subdural, epidural or cord trauma with deep trigger point injections particularly in the neck region. Special attention to technique and avoiding long needles is paramount to minimizing these risks.

#### **42. Cerebral Abscess in Patient with Fat Graft Following Vestibular Schwannoma Resection**

Thielemann, Sandeep Rana Allegheny General Hospital, Pittsburgh, Pennsylvania, United States

**Introduction:** Necrosis of fat graft following translabyrinthine acoustic neuroma surgery is an infrequent entity recognized within the Otolaryngology and Neurosurgery communities with a presumed reactive, inflammatory etiology. We present a case of cerebral abscess in a patient who had received fat grafts following translabyrinthine acoustic neuroma resection. Clinical diagnosis of fat necrosis was considered as a possible etiology.

#### **Patients (or Materials) and Methods:**

Case study of a 71 year old female with a past medical history of right-sided translabyrinthine vestibular schwannoma resection three months prior who presented with a one day history of right-sided occipital headache, nausea, vomiting, and a two week history of vertiginous sensation. She was afebrile, and had persistent post-operative right-sided facial weakness and right-sided dysmetria on physical examination. Her MRI brain demonstrated persistent, impressive 1.5 cm right middle cerebellar peduncle and right cerebellar edema, with a ringlike rim of enhancement encircling the medial component of the surgical fat packing concerning for post-operative cerebral abscess versus fat necrosis.

**Results:** Surgical exploration performed following admission revealed discoloration and liquefactive degeneration of one of the fat grafts utilized for packing, and specimens were sent for culture and pathology. Subsequent microbiology reports confirmed an infection of *Actinomyces meyeri*, with pathology investigation confirming isolated gram positive cocci.

**Conclusion:** An interesting Neuroradiological presentation of cerebral abscess in a patient who had received fat graft for translabyrinthine acoustic neuroma resection.