

FIRST-PASS DISTAL THROMBECTOMY WITH TIGERTRIEVER™ 13



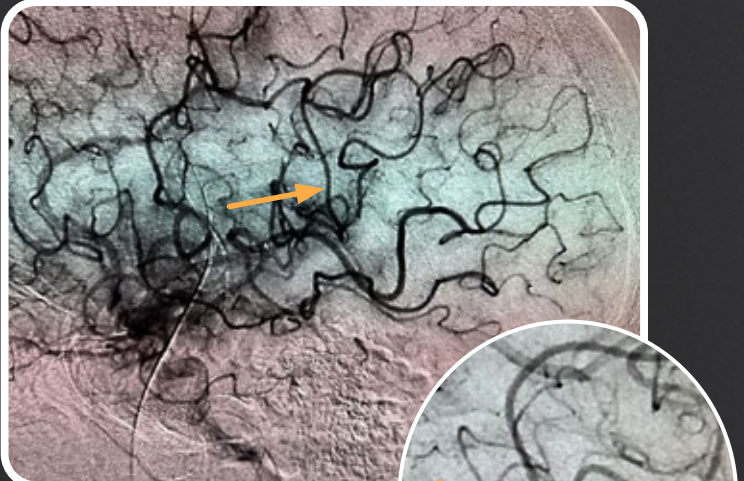
Dr. Alex Solich
Neurointerventionalist
Karolinska University Hospital
Stockholm, Sweden

BACKGROUND: M4 occlusion

Active technology with TIGERTRIEVER™ 13 facilitated immediate clot integration. Reduction of radial force minimized the risk of dragging against the vessel wall during removal.

RESULT: First-pass TICI 3

Significant improvement in patient's stroke symptoms
- NIHSS 11p to 3 one day post-procedure.



X1 Distance: 0.84 mm

