

## FIRST-PASS RECANALIZATION IN DISTAL M2 WITH TIGERTRIEVER™

### CASE OVERVIEW

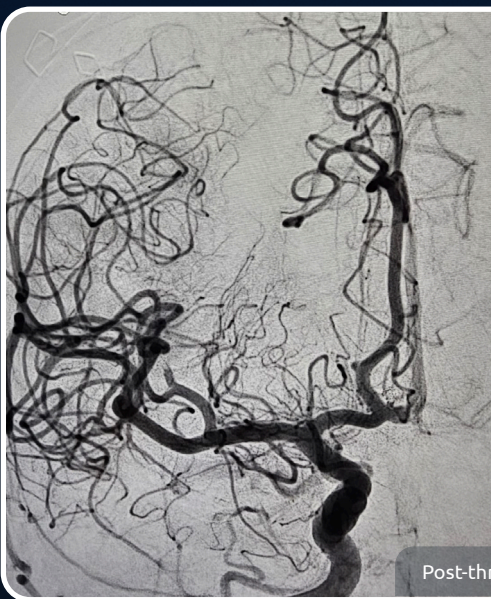
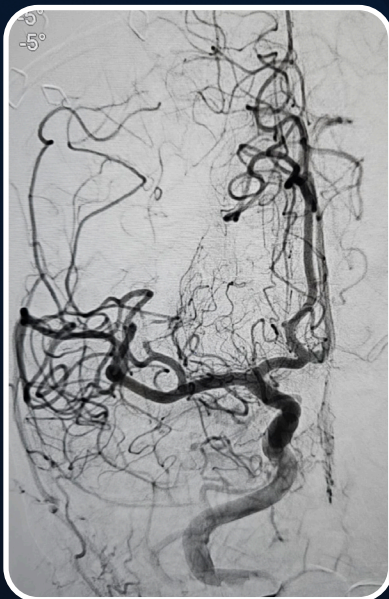**Treated by:** Dr. Ran Brauner, Rabin Medical Center, Tel Aviv, Israel

**Patient background:** 85-year-old female patient with grade 4 SAH. Calcified thrombus to distal M2 during endovascular therapy for ruptured ACOM aneurysm.

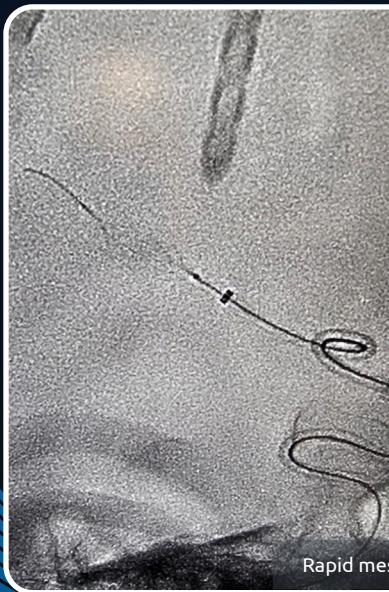
**Set-up:** Ballast™, 5-French Sofia™, SL-10®, TRAXCESS® 14

### RESULTS

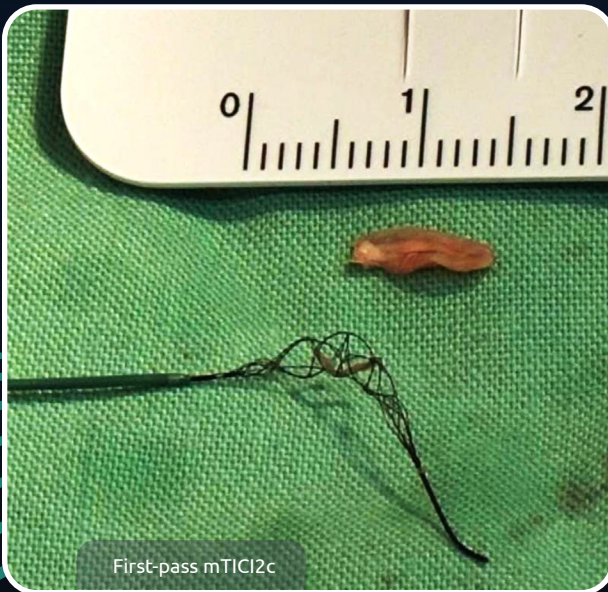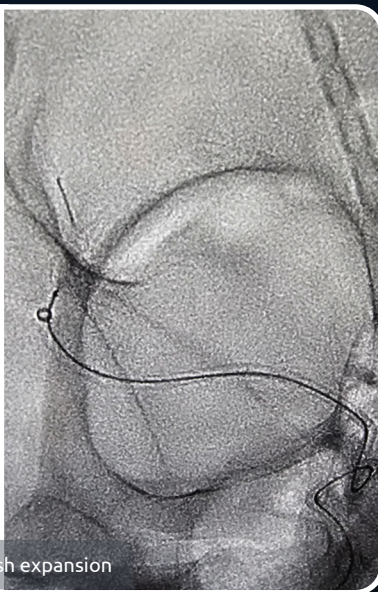
First-pass mTICI2c with rapid expansion of TIGERTRIEVER™ 13.



Post-thrombectomy with TIGERTRIEVER



Rapid mesh expansion



First-pass mTICI2c