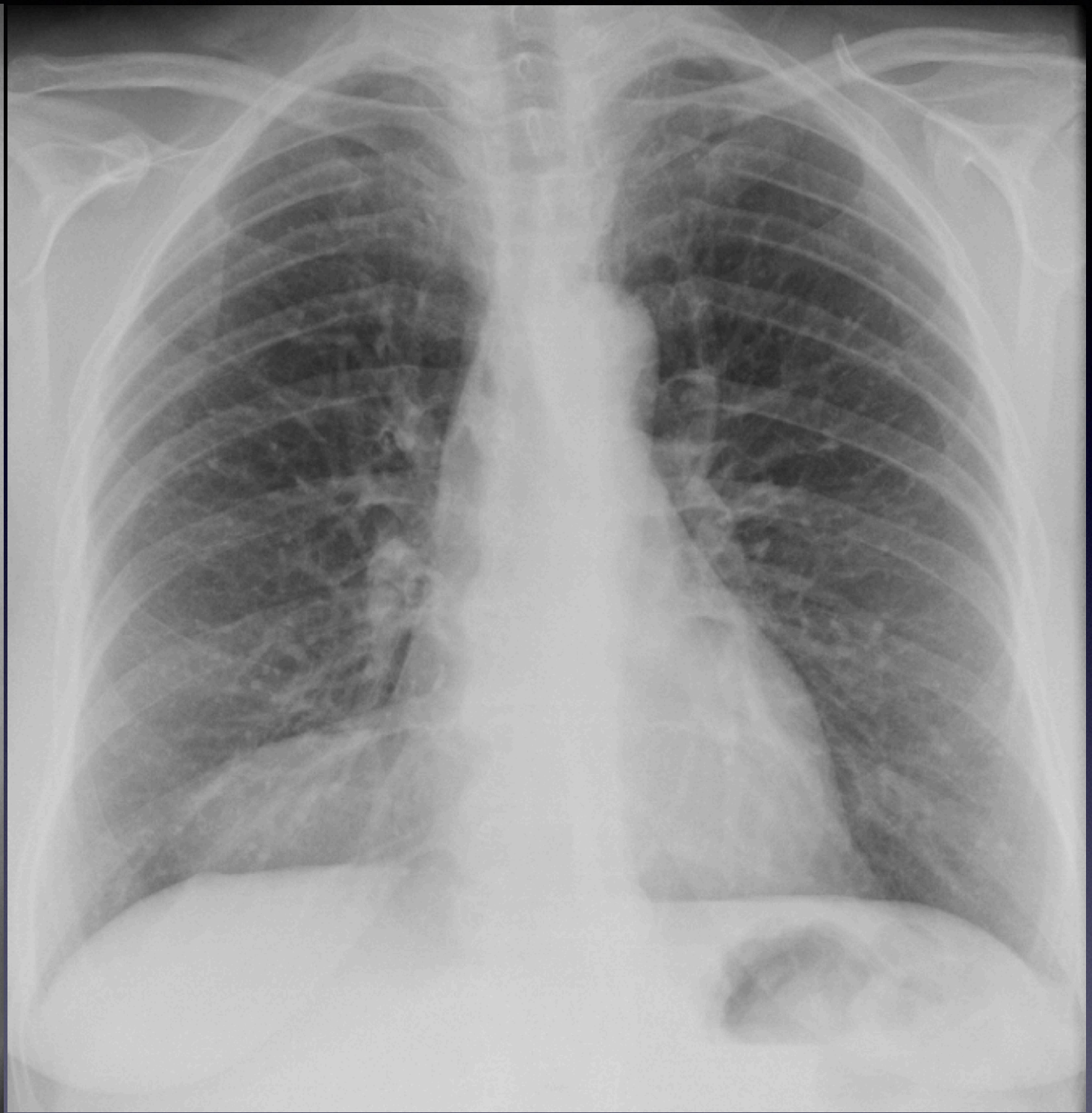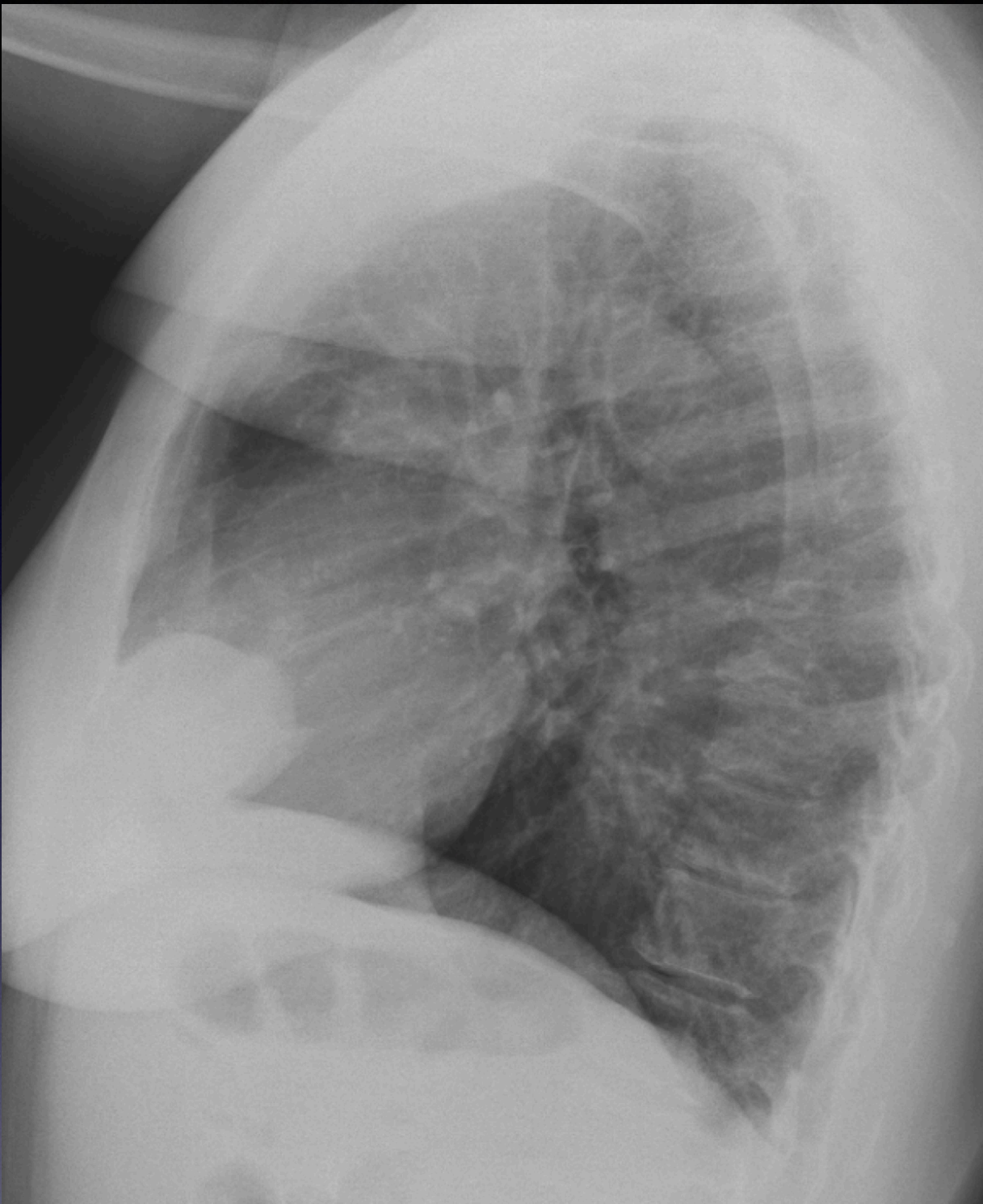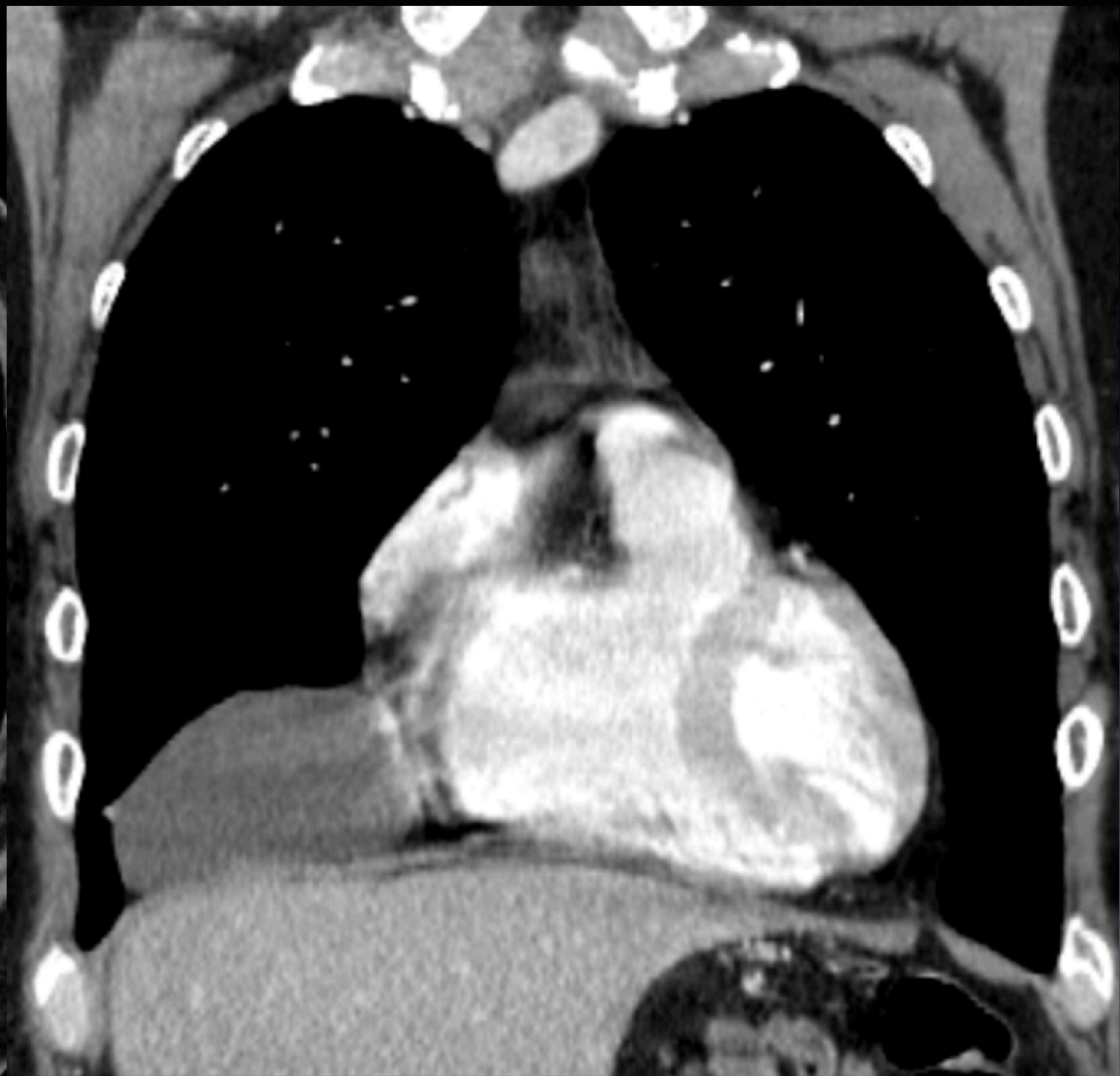
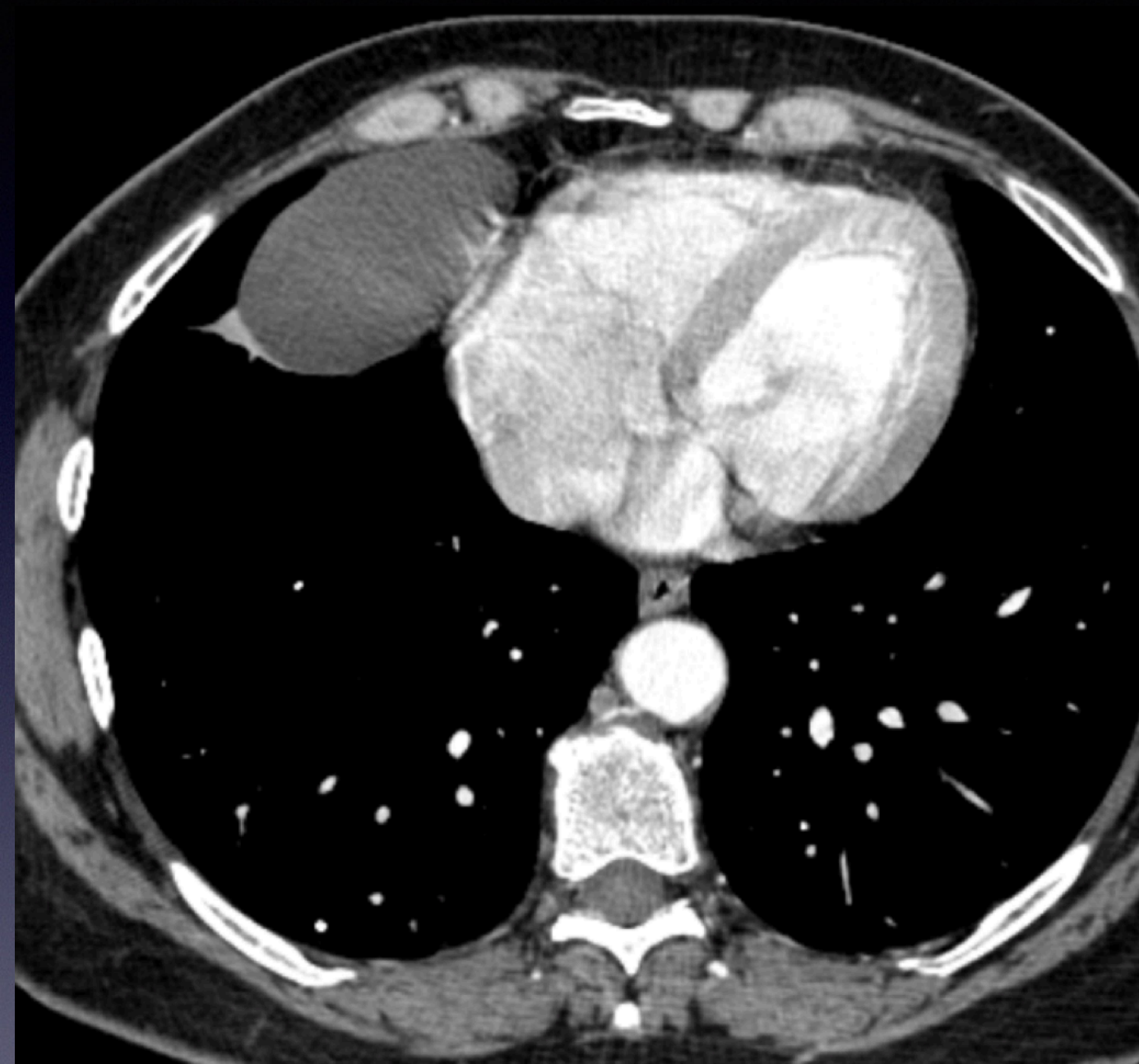




@TanMohammedMD



@TanMohammedMD

Imaging Findings and Differential Diagnosis

- CXR


- fairly well-circumscribed right anterior mediastinal mass (better margins on lateral view)

- CT

- ovoid-shaped fluid density mass in close proximity to right heart and pericardium (no internal gas or septation)

- Differential Diagnosis

- pericardial fat pad
- thymic lesion
- mediastinal teratoma
- Morgagni hernia



@TanMohammedMD

Pericardial Cyst

- benign congenital anomalies of middle mediastinum
- Usually asymptomatic & discovered incidentally
- MC location - right anterior cardiophrenic angle
- **Imaging Findings:**
 - CXR
 - mass-like opacity at cardiophrenic sulcus
 - can be of different shapes & are not always round
 - may change in shape & size w/ inspiration & position
 - CT
 - well-defined, non-enhancing, fluid-attenuation, rounded mass next to the pericardium
- **Treatment:**
 - Often, none necessary
 - Surgery if infected/symptomatic



@TanMohammedMD