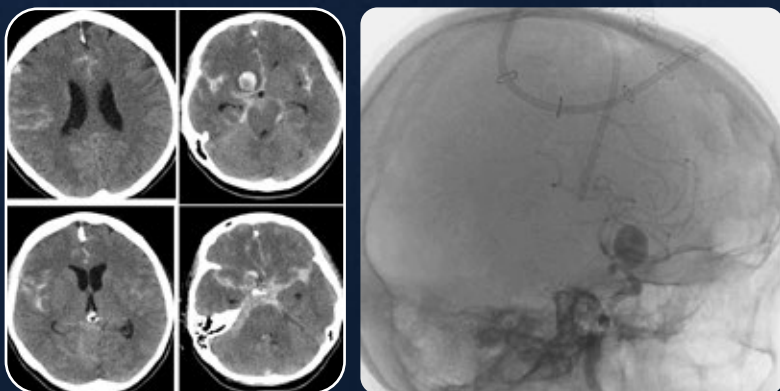


STABLE COILING IN A 15 MM ANEURYSM WITH COMANECI™

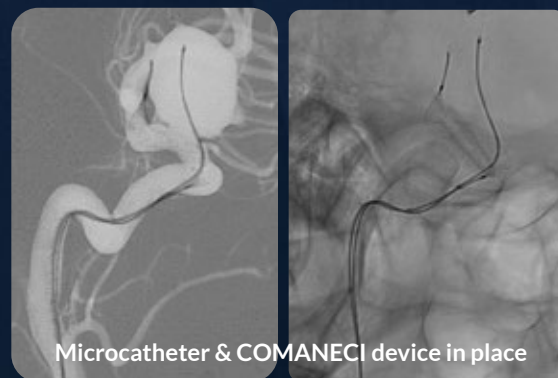
Dr. Torleif Sandner
München Klinik
Bogenhausen, Germany

A 54 year-old patient experienced short unconsciousness following a fall. Scans showed acute SAH due to bleeding in a large ICA aneurysm (15 mm).

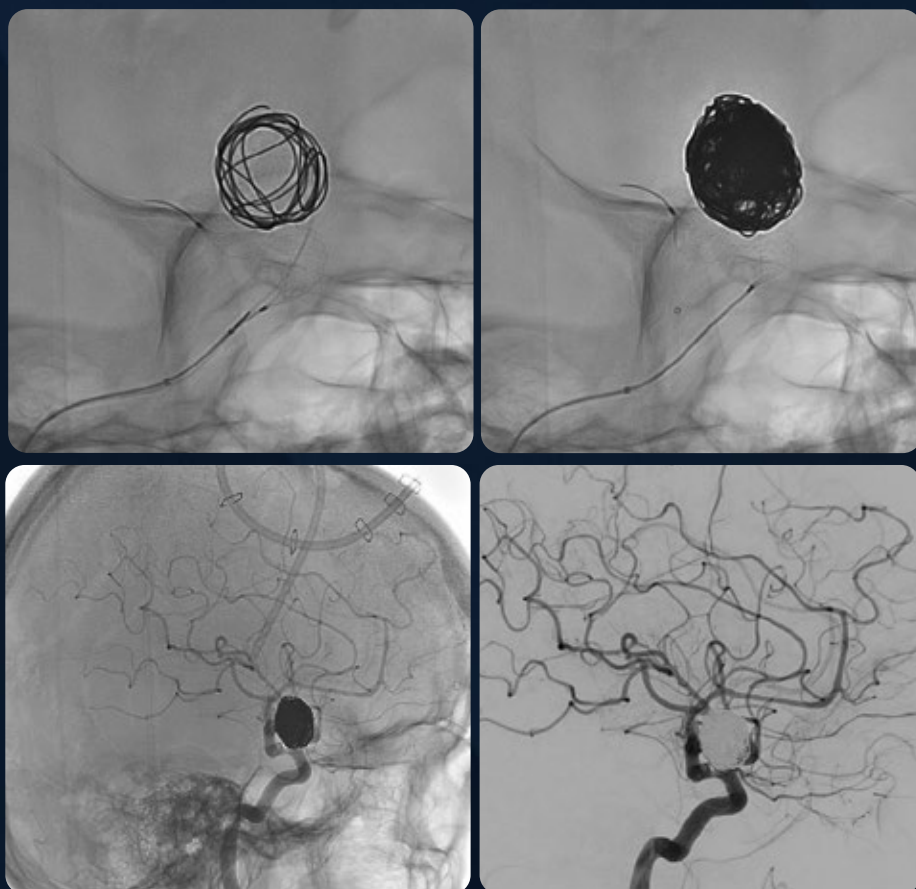INITIAL CCT



DEVICE DEPLOYMENT



PHYSICIAN CONTROLLED COMFORMABILITY



2-WEEK CCT

