



**MonnaLisa Touch™**  
**Il riconoscimento della  
comunità scientifica  
internazionale**

**Raccolta di articoli scientifici a revisione paritaria**

**Settembre 2017**

**MonnaLisa Touch™**

# Indice

**A 12-week treatment with fractional CO<sub>2</sub> laser for vulvovaginal atrophy: a pilot study.**

Salvatore S. et al. *Climacteric*. 2014 Aug; 17(4):363-9. Epub 2014 Jun 5.

**Microablative fractional CO<sub>2</sub> laser improves dyspareunia related to vulvovaginal atrophy: a pilot study.**

Salvatore S. et al. *Journal of Endometriosis and Pelvic Pain Disorders*. 2014; 6(3):150-6. Epub 2014 Jun 20.

**Microscopic and ultrastructural modifications of postmenopausal atrophic vaginal mucosa after fractional carbon dioxide.**

Zerbinati N. et al. *Lasers in Medical Science*. 2015 Jan; 30(1):429-36. Epub 2014 Nov 20.

**Sexual function after fractional microablative CO<sub>2</sub> laser in women with vulvovaginal atrophy.**

Salvatore S. et al. *Climacteric*. 2015 Apr; 18(2):219-25. Epub 2014 Dec 16.

**Vulvo-vaginal atrophy: a new treatment modality using thermos-ablative fractional CO<sub>2</sub> laser.**

Perino A. et al. *Maturitas*. 2015 Mar; 80(3):296-301. Epub 2014 Dec 25.

**Histological study on the effects of microablative fractional CO<sub>2</sub> laser on atrophic vaginal tissue: an ex vivo study.**

Salvatore S. et al. *Menopause*. 2015 Aug; 22(8):845-9.

**The use of pulsed CO<sub>2</sub> laser for the treatment of vulvovaginal atrophy.**

Salvatore S. et al. *Current Opinion in Obstetrics and Gynecology*. 2015 Dic; 27(6):504-8.

**Fractional CO<sub>2</sub> laser for vulvovaginal atrophy (VVA) dyspareunia relief in breast cancer survivors.**

Pieralli A. et al. *Archives of Gynecology and Obstetrics*. 2016 Oct; 294(4): 841-6. Epub 2016 May 12.

**Is vaginal fractional CO<sub>2</sub> laser treatment effective in improving overactive bladder symptoms in post-menopausal patients? Preliminary results.**

Perino A. et al. *Eur Rev Med Pharmacol Sci*. 2016 Jun; 20(12):2491-7.

**The effect of microablative fractional CO<sub>2</sub> laser on vaginal flora of postmenopausal women.**

Athanasios S. et al. *Climacteric*. 2016 Oct; 19(5):512-8. Epub 2016 Aug 24.

**An assessment of the safety and efficacy of a fractional CO<sub>2</sub> laser system for the treatment of vulvovaginal atrophy.**

Sokol E.R. et al. *Menopause*. 2016 Oct; 23(10):1102-7.

**Fractional microablative CO<sub>2</sub> laser for vulvovaginal atrophy in women treated with chemotherapy and/or hormonal therapy for breast cancer: a retrospective study.**

Pagano T. et al. *Menopause*. 2016 Oct; 23(10):1108-13.

**The curative effect and feasibility analysis of fractional CO<sub>2</sub> laser in the treatment of vulvovaginal atrophy in postmenopausal women.**

Miao Y. et al. *Chin J Clin Obstet Gynecol*. 2016 July; 17(4):294-7.

**The application of fractional CO<sub>2</sub> laser in the treatment of vulvar lichen sclerosus.**

Li J. et al. *Chin J Clin Obstet Gynecol*. 2016 July; 17(4):298-301.

**Microablative fractional CO<sub>2</sub>-laser therapy and the genitourinary syndrome of menopause: An observational study.**

Pitsouni E. et al. *Maturitas*. 2016 Dec; 94:131-6. Epub 2016 Sep 16.

**Fractional CO<sub>2</sub> laser treatment of the vestibule for patients with vestibulodynia and genitourinary syndrome of menopause: a pilot study.**

Murina F. et al. *J Sex Med*. 2016 Dec; 13(12):1915-7. Epub 2016 Nov 15.

# Indice

**Fractional CO<sub>2</sub> laser treatment for vaginal atrophy and vulvar lichen sclerosus.**

Baggish M. S. *Journal of Gynecologic Surgery*. 2016 Dec; 32(6): 309-17. Epub 2016, Nov 21.

**Fractional CO<sub>2</sub> laser treatment: a novel approach for stress urinary incontinence management in post-menopausal women.**

González Isaza P. et al. *Urología Colombiana* 2017; 26(1). Epub 2016 Oct 09.

**Fractional CO<sub>2</sub> laser: from skin rejuvenation to vulvo-vaginal reshaping.**

Filippini M. et al. *Photomed Laser Surg*. 2017; 35(3):171-5. Epub 2016 Dec 30.

**Use of a novel fractional CO<sub>2</sub> laser for the treatment of genitourinary syndrome of menopause: 1-year outcomes.**

Sokol E.R. et al. *Menopause*. Epub 2017 Feb 6.

**Safety and long-term efficacy of fractional CO<sub>2</sub> laser treatment in women suffering from genitourinary syndrome of menopause.**

Behnia-Willison F. et al. *Eur J Obstet Gynecol Reprod Biol*. June 2017; 213:39-44. Epub 2017 Apr 2.

**Fractional CO<sub>2</sub> laser therapy: a new challenge for vulvovaginal atrophy in postmenopausal women.**

Siliquini G.P. et al. *Climacteric*. Epub 2017 May 15.

**Long-term effect of thermoablative fractional CO<sub>2</sub> laser treatment as a novel approach to urinary incontinence management in women with genitourinary syndrome of menopause.**

González Isaza P. et al. *Int Urogynecol J*. Epub 2017 May 18.

**Laser therapy for the genitourinary syndrome of menopause. A systematic review and meta-analysis.**

Pitsouni E. et al. *Maturitas*. Epub 2017 June 27.

**CO<sub>2</sub>-laser for the genitourinary syndrome of menopause. How many laser sessions?**

Athanasίου S. et al. *Maturitas*. 2017 Oct; 104:24-8. Epub 2017 Jul 21.

**Lasers for pelvic floor dysfunctions: is there evidence?**

Lang P. et al. *Curr Opin Obstet Gynecol*. Epub 2017 Jul 29.

**Randomized, double-blind, placebo-controlled clinical trial for evaluating the efficacy of fractional CO<sub>2</sub> laser compared with topical estriol in the treatment of vaginal atrophy in postmenopausal women**

Cruz V.L. et al. *Menopause*. Epub 2017 Jul 31.

**Microablative fractional CO<sub>2</sub> laser for the genitourinary syndrome of menopause: power of 30 or 40 W?**

Pitsouni E. et al. *Lasers Med Sci*. Epub 2017 Aug 2.

**Sexual function in women suffering from genitourinary syndrome of menopause treated with fractionated CO<sub>2</sub> laser.**

Salvatore S. et al. *Sex Med Rev*. Epub 2017 Aug 23.

**Long-term reliability of fractioned CO<sub>2</sub> laser as a treatment for vulvovaginal atrophy (VVA) symptoms.**

Pieralli A. et al. *Arch Gynecol Obstet*. Epub 2017 Sep 2.

**Fractional CO<sub>2</sub> laser of the vagina for genitourinary syndrome of menopause: Is the out-of-pocket cost worth the outcome of treatment?.**

Lang P. et al. *Lasers Surg Med*. Epub 2017 Sep 7.

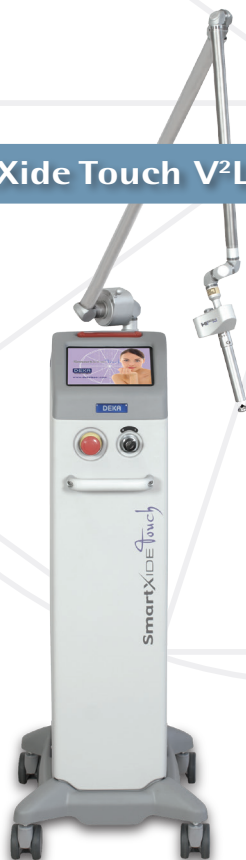# MonnaLisa Touch™

L'unico trattamento eseguito  
solo con sistemi Laser DEKA

SmartXide<sup>2</sup> V<sup>2</sup>LR



SmartXide Touch V<sup>2</sup>LR



## Editoriale

Quando, nel 2009, mi sono avvicinato al mondo del laser in ginecologia ho dovuto vincere un grande scetticismo e una discreta paura che scaturivano dalla mia ignoranza in questo settore.

Nelle procedure di validazione e valutazione di MonnaLisa Touch™, laser Deka a CO<sub>2</sub> frazionato, ho potuto constatare le incredibili capacità rigenerative che questo strumento riesce a produrre.

La validazione di MonnaLisa Touch™ ha seguito diverse fasi che hanno ricalcato quanto viene fatto in ambito farmacologico per nuovi farmaci. Questo approccio è tutt'altro che comune persino in molte innovative tecniche chirurgiche.

Una prima fase di safety e dose finding è stata sviluppata con uno studio ex-vivo dove il tessuto vaginale in eccesso, di donne sottoposte ad intervento chirurgico per prolasso, è stato trattato con cinque protocolli di s e t t a g g i o diverso del laser.

Siamo cos'irrucciati ad individuare i parametri che garantivano la massima sicurezza ed efficacia, oltre che ad osservare la modalità di azione, almeno sulla lamina propria vaginale, di questa procedura.

Gli studi successivi sono stati importanti per determinare un numero medio di trattamenti (pari a 3) da offrire alle donne trattate per atrofia vaginale post-menopausale. Abbiamo anche riportato in maniera oggettiva e soggettiva, con strumenti indicanti la percezione del miglioramento e con ulteriori dati istologici l'efficacia altissima del trattamento per tutti i sintomi di atrofia vaginale, con conseguente miglioramento della qualità di vita e della funzione sessuale.

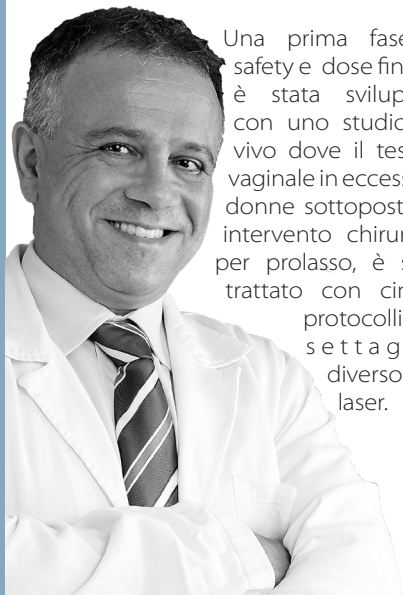
Tantissimi altri studi sono ora in corso all' Ospedale San Raffaele di Milano e potrebbero a breve introdurre nuove indicazioni per questa modalità terapeutica.

Per concludere un ringraziamento a tutta la mia équipe senza il cui contributo non sarebbe stato possibile produrre i dati pubblicati fino ad ora relativamente al MonnaLisa Touch™, così come un grazie va rivolto al Prof. Calligaro, al Prof. Zerbinati e alla Prof.ssa Nappi per la fondamentale collaborazione.

**DR. STEFANO SALVATORE**

Resp. Ambulatorio di uroginecologia  
Ospedale S. Raffaele di Milano

Presidente dell'Associazione europea  
uroginecologica (EUGA)



# A 12-week treatment with fractional CO<sub>2</sub> laser for vulvovaginal atrophy: a pilot study

Salvatore S<sup>1</sup>, Nappi RE<sup>2</sup>, Zerbinati N<sup>3</sup>, Calligaro A<sup>4</sup>, Ferrero S<sup>5</sup>,  
Origoni M<sup>1</sup>, Candiani M<sup>1</sup>, Leone Roberti Maggiore U<sup>1</sup>

1: San Raffaele Hospital, Milan - Italy. 2: Policlinico S. Matteo, University of Pavia, Pavia - Italy.

3: University of Insubria, Varese - Italy. 4: University of Pavia, Pavia - Italy.

5: San Martino Hospital, University of Genoa, Genoa - Italy.



## Abstract

### Objective

This pilot study aimed to assess the efficacy and feasibility of fractional CO<sub>2</sub> laser in the treatment of vulvovaginal atrophy (VVA) in postmenopausal women.

### Methods

VVA symptoms were assessed before and after three applications of laser over 12 weeks in 50 women (age 59.6 ± 5.8 years) dissatisfied with previous local estrogen therapies. Subjective (visual analog scale) and objective (Vaginal Health Index Score, VHIS) measures were used during the study period to assess VVA. Quality of life was measured by using the SF-12. A subjective scale to evaluate the degree of pain related to the laser application and the degree of difficulty to perform the laser procedure was used.

### Results

Fractional CO<sub>2</sub> laser treatment was effective to improve VVA symptoms (vaginal dryness, vaginal burning, vaginal itching, dyspareunia, dysuria;  $p < 0.001$ ) at 12-week follow-up, as well as the VHIS (13.1 ± 2.5 at baseline vs. 23.1 ± 1.9;  $p < 0.001$ ). Both physical and mental scores of quality of life were significantly improved in comparison with baseline ( $p < 0.001$ ). Satisfaction with the laser procedure was reported by 42 women (84%) and a minimal discomfort was experienced at the first laser application, mainly because of the insertion and the movements of the probe. Finally, the technique was very easy to perform in all women starting from the second application at week 4 and no adverse events were recorded during the study period.

### Conclusions

A 12-week treatment with the fractional CO<sub>2</sub> laser was feasible and induced a significant improvement of VVA symptoms by ameliorating vaginal health in postmenopausal women. Further controlled studies should be performed to confirm the present data and to assess the long-term effects of the laser procedure on vaginal tissues.

## Microablative fractional CO<sub>2</sub> laser improves dyspareunia related to vulvovaginal atrophy: a pilot study

Salvatore S<sup>1</sup>, Leone Roberti Maggiore U<sup>1</sup>, Origoni M<sup>1</sup>, Parma M<sup>1</sup>, Quaranta L<sup>1</sup>, Sileo F<sup>1</sup>, Cola A<sup>1</sup>, Bainsi I<sup>1</sup>, Ferrero S<sup>2</sup>, Candiani M<sup>1</sup>, Zerbinati N<sup>3</sup>

1: San Raffaele Hospital, Milan – Italy. 2: San Martino Hospital, University of Genoa, Genoa – Italy. 3: University of Insubria, Varese – Italy.



### Abstract

This pilot study aimed to assess the efficacy in treating sexually active menopausal patients who had dyspareunia related to vulvovaginal atrophy (VVA).

The intensity of VVA symptoms was recorded for each patient. Patients were administered the Short Form 12 (SF-12) and the female sexual function index (FSFI) to assess quality of life and sexual function, respectively. An objective evaluation of female urogenital health was performed using the Gloria Bachman Vaginal Health Index (VHI).


At 12-week follow-up, the laser treatment was efficacious in improving dyspareunia in 100% of patients included in the study (n = 15). The intensity of dyspareunia significantly decreased from baseline ( $8.7 \pm 1.0$ ) to 12-week follow-up ( $2.2 \pm 1.0$ ;  $p < 0.001$ ). In addition, all other VVA symptoms significantly ameliorated at the same follow-up. Furthermore, after the treatment, a significant improvement in quality of life (QoL) and sexual function were shown.

This pilot study demonstrated that treatment with the microablative fractional CO<sub>2</sub> laser of patients with dyspareunia related to VVA was efficacious at 12-week follow-up.

# Microscopic and ultrastructural modifications of postmenopausal atrophic vaginal mucosa after fractional carbon dioxide laser treatment

Zerbinati N<sup>1</sup>, Serati M<sup>1</sup>, Origoni M<sup>2</sup>, Candiani M<sup>2</sup>, Iannitti T<sup>3</sup>,  
Salvatore S<sup>2</sup>, Marotta F<sup>4</sup>, Calligaro A<sup>5</sup>

1: University of Insubria, Varese – Italy. 2: San Raffaele Hospital, Milan – Italy. 3: University of Leeds, Leeds – United Kingdom.  
4: ReGenera Research Group for Aging Intervention, Milan – Italy. 5: University of Pavia, Pavia – Italy.



## Abstract


Vaginal atrophy occurring during menopause is closely related to the dramatic decrease in ovarian estrogens due to the loss of follicular activity.

Particularly, significant changes occur in the structure of the vaginal mucosa, with consequent impairment of many physiological functions. In this study, carried out on bioptic vaginal mucosa samples from postmenopausal, nonestrogenized women, we present microscopic and ultrastructural modifications of vaginal mucosa following fractional carbon dioxide (CO<sub>2</sub>) laser treatment. We observed the restoration of the vaginal thick squamous stratified epithelium with a significant storage of glycogen in the epithelial cells and a high degree of glycogen-rich shedding cells at the epithelial surface.

Moreover, in the connective tissue constituting the lamina propria, active fibroblasts synthesized new components of the extracellular matrix including collagen and ground substance (extrafibrillar matrix) molecules.

Differently from atrophic mucosa, newly-formed papillae of connective tissue indented in the epithelium and typical blood capillaries penetrating inside the papillae, were also observed. Our morphological findings support the effectiveness of fractional CO<sub>2</sub> laser application for the restoration of vaginal mucosa structure and related physiological trophism. These findings clearly coupled with striking clinical relief from symptoms suffered by the patients before treatment remodeling of vaginal connective tissue without causing damage to surrounding tissue.





Climacteric - Vol.18, No. 2, 2015. Epub 2014 Dec 16

# Sexual function after fractional microablative CO<sub>2</sub> laser in women with vulvovaginal atrophy

Salvatore S<sup>1</sup>, Nappi RE<sup>2</sup>, Parma M<sup>1</sup>, Chionna R<sup>1</sup>, Lagona F<sup>1</sup>, Zerbinati N<sup>3</sup>, Ferrero S<sup>4</sup>, Origoni M<sup>1</sup>, Candiani M<sup>1</sup>, Leone Roberti Maggiore U<sup>1</sup>

1: San Raffaele Hospital, Milan – Italy. 2: Policlinico S. Matteo, University of Pavia, Pavia – Italy. 3: University of Insubria, Varese – Italy. 4: San Martino Hospital, University of Genoa, Genoa, Italy.

## Abstract

### Objective

To investigate the effects of fractional microablative CO<sub>2</sub> laser on sexual function and overall satisfaction with sexual life in postmenopausal women with vulvovaginal atrophy (VVA).

### Method

This prospective study included 77 postmenopausal women (mean age 60.6 ± 6.2 years) treated for VVA symptoms with the fractional microablative CO<sub>2</sub> laser system (SmartXide<sup>2</sup> V<sup>2</sup>LR, MonaLisa Touch<sup>®</sup>, DEKA, Florence, Italy). Sexual function and quality of life were evaluated with the Female Sexual Function Index (FSFI) and the Short Form 12 (SF-12), respectively, both at baseline and at 12-week follow-up. A 10-mm visual analog scale was used to measure the overall satisfaction with sexual life and the intensity of VVA symptoms (vaginal burning, vaginal itching, vaginal dryness, dyspareunia and dysuria) before and after the study period.

### Results

We observed a significant improvement in the total score and the scores in each specific domain of the FSFI at 12-week follow-up compared to baseline ( $p < 0.001$ ). After concluding the laser treatment, the overall satisfaction with sexual life significantly improved ( $p < 0.001$ ). Seventeen (85%) out of 20 (26%) women, not sexually active because of VVA severity at baseline, regained a normal sexual life at the 12-week follow-up. Finally, we also found a significant improvement in each VVA symptom ( $p < 0.001$ ) and in quality-of-life evaluation, both for the scores in the physical ( $p = 0.013$ ) and mental ( $p = 0.002$ ) domains.

### Conclusions

Fractional microablative CO<sub>2</sub> laser treatment is associated with a significant improvement of sexual function and satisfaction with sexual life in postmenopausal women with VVA symptoms.

Maturitas - Vol. 80, No. 3, 2015. Epub 2014 Dec 25

# Vulvo-vaginal atrophy: A new treatment modality using thermo-ablative fractional CO<sub>2</sub> laser

Perino A<sup>1</sup>, Calligaro A<sup>2</sup>, Forlani F<sup>1</sup>, Tiberio C<sup>1</sup>, Cucinella G<sup>1</sup>,  
Svelato A<sup>1</sup>, Saitta S<sup>3</sup>, Calagna G<sup>1</sup>

1: University Hospital "P. Giaccone", Palermo – Italy, 2: University of Pavia, Pavia – Italy,  
3: University of Messina, Messina – Italy.



## Abstract

### Objective

To evaluate the efficacy and feasibility of thermo-ablative fractional CO<sub>2</sub> laser for the treatment of symptoms related to vulvo-vaginal atrophy (VVA) in post-menopausal women.

### Methods

From April 2013 to December 2013, post-menopausal patients who complained of one or more VVA-related symptoms and who underwent vaginal treatment with fractional CO<sub>2</sub> laser were enrolled in the study. At baseline (T0) and 30 days post-treatment (T1), vaginal status of the women was evaluated using the Vaginal Health Index (VHI), and subjective intensity of VVA symptoms was evaluated using a visual analog scale (VAS). At T1, treatment satisfaction was evaluated using a 5-point Likert scale.

### Results

During the study period, a total of 48 patients were enrolled. Data indicated a significant improvement in VVA symptoms (vaginal dryness, burning, itching and dyspareunia) ( $P < 0.0001$ ) in patients who had undergone 3 sessions of vaginal fractional CO<sub>2</sub> laser treatment. Moreover, VHI scores were significantly higher at T1 ( $P < 0.0001$ ). Overall, 91.7% of patients were satisfied or very satisfied with the procedure and experienced considerable improvement in quality of life (QoL). No adverse events due to fractional CO<sub>2</sub> laser treatment occurred.

### Conclusions

Thermo-ablative fractional CO<sub>2</sub> laser could be a safe, effective and feasible option for the treatment of VVA symptoms in post-menopausal women.

# Histological study on the effects of microablative fractional CO<sub>2</sub> laser on atrophic vaginal tissue: an ex vivo study

Salvatore S<sup>1</sup>, Leone Roberti Maggiore U<sup>1</sup>, Athanasiou S<sup>2</sup>, Origoni M<sup>1</sup>, Candiani M<sup>1</sup>, Calligaro A<sup>3</sup>, Zerbinati N<sup>4</sup>

1: San Raffaele Hospital, Milan – Italy. 2: National and Kapodistrian University of Athens, Athens – Greece. 3: University of Pavia, Pavia – Italy. 4: University of Insubria, Varese – Italy.



## Abstract

### Objective

Microablative fractional CO<sub>2</sub> laser has been proven to determine tissue remodeling with neof ormation of collagen and elastic fibers on atrophic skin. The aim of our study is to evaluate the effects of microablative fractional CO<sub>2</sub> laser on postmenopausal women with vulvovaginal atrophy using an ex vivo model.

### Methods

This is a prospective ex vivo cohort trial. Consecutive postmenopausal women with vulvovaginal atrophy managed with pelvic organ prolapse surgical operation were enrolled. After fascial plication, the redundant vaginal edge on one side was treated with CO<sub>2</sub> laser (SmartXide<sup>2</sup>; DEKA Laser, Florence, Italy). Five different CO<sub>2</sub> laser setup protocols were tested. The contralateral part of the vaginal wall was always used as control. Excessive vagina was trimmed and sent for histological evaluation to compare treated and nontreated tissues. Microscopic and ultrastructural aspects of the collagenic and elastic components of the matrix were studied, and a specific image analysis with computerized morphometry was performed. We also considered the fine cytological aspects of connective tissue proper cells, particularly fibroblasts.

### Results

During the study period, five women were enrolled, and 10 vaginal specimens were finally retrieved. Four different settings of CO<sub>2</sub> laser were compared. Protocols were tested twice each to confirm histological findings. Treatment protocols were compared according to histological findings, particularly in maximal depth and connective changes achieved. All procedures were uneventful for participants.

### Conclusions


This study shows that microablative fractional CO<sub>2</sub> laser can produce a remodeling of vaginal connective tissue without causing damage to surrounding tissue.

Current Opinion in Obstetrics and Gynecology - Vol. 27, No. 6, 2015

# The use of pulsed CO<sub>2</sub> lasers for the treatment of vulvovaginal atrophy

Salvatore S<sup>1</sup>, Athanasiou S<sup>2</sup>, Candiani M<sup>1</sup>

1: San Raffaele Hospital, Milan – Italy. 2: National and Kapodistrian University of Athens, Athens – Greece.



## Abstract

### Purpose of Review

This article reviews the literature regarding the safety and efficacy of the use of a pulsed CO<sub>2</sub> laser for the treatment of vulvovaginal atrophy (VVA).

### Recent Findings

Prospective observational studies have demonstrated histological changes after the use of pulsed CO<sub>2</sub> laser vaginally in atrophic conditions. Increased collagen and extracellular matrix production has been reported together with an increase in the thickness of the vaginal epithelium with the formation of new papilla. Three different observational studies reported a significant improvement of VVA assessed subjectively (with a 10-point visual analogue scale) and objectively (using the Vaginal Health Index) after a cycle of three treatments of pulsed CO<sub>2</sub> laser. Also sexual function (assessed with the Female Sexual Function Index) and quality of life (evaluated with the SF12 questionnaire) significantly improved. No complications or sideeffects were reported during or after the laser procedure that was performed in an outpatient setting.

### Summary

Increasing evidence with histological and clinical data supports the use of pulsed CO<sub>2</sub> lasers in the treatment of VVA; however, no randomized control trial (sham versus treatment) has yet been produced and no data on the duration of therapy are currently available.

Archives of Obstetrics and Gynecology - Vol. 249, No. 4, 2016. Epub 2016 May 12

# Fractional CO<sub>2</sub> laser for vulvovaginal atrophy (VVA) dyspareunia relief in breast cancer survivors

Pieralli A<sup>1</sup>, Fallani MG<sup>1</sup>, Becorpi A<sup>1</sup>, Bianchi C<sup>1</sup>, Corioni S<sup>1</sup>, Longinotti M<sup>1</sup>, Tredici Z<sup>1</sup>, Guaschino S<sup>1</sup>

<sup>1</sup>: Careggi University Hospital, Florence - Italy.



## Abstract

### Purpose

The aim of this study was to evaluate the efficacy of fractional CO<sub>2</sub> laser therapy in breast cancer survivors as a therapeutic method for vulvovaginal atrophy (VVA) dyspareunia.

### Methods

50 patients (mean age 53.3 years) underwent fractional microablative CO<sub>2</sub> laser treatment for dyspareunia in oncological menopause (mean time of menopause 6.6 years). The Gloria Bachmann's Vaginal Health Index (VHI) score was chosen as system to evaluate the presence of VVA and its improvement after the treatment. Intensity of dyspareunia was evaluated using a visual analog scale (VAS).

### Results

Data indicated a significant improvement in VVA dyspareunia ( $p < 1.86e-22$ ) in breast cancer survivors who had undergone 3 sessions of vaginal fractional CO<sub>2</sub> laser treatment. Moreover, VHI scores were significantly higher 30 days post-treatment (T4) ( $p < 0.0001$ ). 76 % of patients were satisfied or very satisfied with the treatment results. The majority (52 %) of patients were satisfied after a long-term follow-up (mean time 11 months). No adverse events due to fractional CO<sub>2</sub> laser treatment occurred.

### Conclusions

The treatment with fractionated CO<sub>2</sub> laser appeared to be a feasible and effective treatment for VVA dyspareunia in breast cancer survivors with contraindications to hormonal treatments.

# Is vaginal fractional CO<sub>2</sub> laser treatment effective in improving overactive bladder symptoms in post-menopausal patients? Preliminary results

Perino A<sup>1</sup>, Cucinella G<sup>2</sup>, Gugliotta G<sup>3</sup>, Saitta S<sup>4</sup>, Polito S<sup>5</sup>,  
Adile B<sup>2</sup>, Marci R<sup>5</sup>, Calagna G<sup>1</sup>

1: University Hospital, Palermo – Italy. 2: 'Villa Sofia-Cervello' Hospital, Palermo – Italy. 3: University of Messina, Messina – Italy.  
4: "Barone I. Romeo" Hospital, Patti (ME) – Italy. 5: University of Ferrara, Ferrara - Italy.



## Abstract

### Objective

To evaluate the role of vaginal fractional CO<sub>2</sub> laser treatment in the relief of Overactive Bladder (OAB) symptoms in post-menopausal women.

### Patients and Methods

Post-menopausal women who complained of one or more symptoms related to vulvo-vaginal atrophy (VVA), who experienced symptoms of OAB and who underwent vaginal treatment with fractional CO<sub>2</sub> laser were enrolled in the study. At baseline (T0) and 30 days post-treatment (T1), vaginal status (using Vaginal Health Index - VHI), subjective intensity of VVA symptoms (using a visual analog scale - VAS) and micturition diary were evaluated. OAB symptoms were also assessed using a validated questionnaire.

### Results

Thirty patients were enrolled. A statistically significant improvement in VVA symptoms was observed and in VHI at T1 ( $p < 0.0001$ ). A significant improvement was also identified in the micturition diary, in number of urge episodes and OAB-q ( $p < 0.0001$ ). Nine of the 30 patients suffered from incontinence episodes and had improved at T1.

### Conclusions

We showed that fractionated CO<sub>2</sub> laser vaginal treatment has proved to be effective in improving OAB symptoms in post-menopausal women. Moreover, it is a safe and efficacious measure for the relief of VVA related conditions. Further long-term studies are needed to confirm these preliminary results.

Climacteric – Vol. 19, No. 5, 2016. Epub 2016 Aug 2


# The effect of microablative fractional CO<sub>2</sub> laser on vaginal flora of postmenopausal women

Athanasίου S<sup>1</sup>, Pitsouni E<sup>1,2</sup>, Antonopoulou S<sup>3</sup>, Zacharakis D<sup>1</sup>,  
Salvatore S<sup>4</sup>, Falagas ME<sup>2,5,6</sup>, Grigoriadis T<sup>7</sup>

1: National and Kapodistrian University of Athens, Athens – Greece. 2: AIBS, Athens – Greece.

3: “G. Gennimatas” General Hospital, Athens – Greece. 4: San Raffaele Hospital, Milan – Italy. 5: IASO General Hospital, Athens – Greece.

6: Tufts University School of Medicine, Boston, MA - USA. 7 : Alexandra Hospital”, Athens - Greece.



## Abstract

### Objectives

To assess the effect of microablative fractional CO<sub>2</sub> laser (MFCO<sub>2</sub>-Laser) therapy on the vaginal microenvironment of postmenopausal women.

### Methods

Three laser therapies at monthly intervals were applied in postmenopausal women with moderate to severe symptoms of genitourinary syndrome of menopause, pH of vaginal fluid >4.5 and superficial epithelial cells on vaginal smear <5%. Vaginal fluid pH values, fresh wet mount microscopy, Gram stain and aerobic and anaerobic cultures were evaluated at baseline and 1 month after each subsequent therapy. Nugent score and Hay-Ison criteria were used to evaluate vaginal flora.

### Results

Fifty-three women (mean age 57.2±5.4 years) participated and completed this study. MFCO<sub>2</sub>-Laser therapy increased Lactobacillus (p<0.001) and normal flora (p<0.001) after the completion of the therapeutic protocol, which decreased vaginal pH from a mean of 5.5±0.8 (initial value) to 4.7±0.5 (p<0.001). The prevalence of Lactobacillus changed from 30% initially to 79% after the last treatment. Clinical signs and symptoms of bacterial vaginosis, aerobic vaginitis or candidiasis did not appear in any participant.

### Conclusions

MFCO<sub>2</sub>-Laser therapy is a promising treatment for improving the vaginal health of postmenopausal women by helping repopulate the vagina with normally existing Lactobacillus species and reconstituting the normal flora to premenopausal status.

Menopause – Vol. 23, No. 10, 2016

# An assessment of the safety and efficacy of a fractional CO<sub>2</sub> laser system for the treatment of vulvovaginal atrophy

Sokol ER<sup>1</sup>, Karram MM<sup>2</sup>

1: Stanford University, Stanford, CA - USA. 2: The Christ Hospital, Cincinnati, OH - USA.



## Abstract

### Objective

The aim of the study was to assess the safety and efficacy of a novel fractional CO<sub>2</sub> laser for the treatment of genitourinary syndrome of menopause (GSM).

### Patients and Methods

Women presenting with GSM and meeting study criteria were enrolled. Examinations at baseline and follow-up (3 mo after final treatment) evaluated dilator tolerance and vaginal pH. Visual analog scales were used to assess pain, vaginal burning, vaginal itching, vaginal dryness, dyspareunia, and dysuria; Vaginal Health Index scores were completed before each treatment and at follow-up; Female Sexual Function Index and Short Form 12 questionnaires were also completed. Participant satisfaction was measured on a 5-point Likert scale (1=very dissatisfied, 5=very satisfied). Women received three laser treatments, 6 weeks apart.

### Results

Thirty women participated (mean age 58.6±8.8 y). None withdrew or were discontinued due to an adverse event; three were lost to follow-up. Average improvement in visual analog scale scoring was 1.7±3.2 for pain, 1.4±2.9 for burning, 1.4±1.9 for itching, 6.1±2.7 for dryness, 5.1±3.0 for dyspareunia, and 1.0±2.4 for dysuria; improvement in average Vaginal Health Index and Female Sexual Function Index scores were statistically significant (P<0.001). Twenty-five of 30 participants (83%) showed increase in comfortable dilator size at 3-month follow up. Before the second and third treatments, 86.6% (26 of 30) of women reported they were better or much better than at the previous treatment; 26 of 27 women (96%) were reportedly satisfied or extremely satisfied at follow-up.

### Conclusions

In this sample, the data suggest that the fractional CO<sub>2</sub> laser is effective and safe for treatment of the symptoms associated with GSM.



# Fractional microablative CO<sub>2</sub> laser for vulvovaginal atrophy in women treated with chemotherapy and/or hormonal therapy for breast cancer: a retrospective study

Pagano T<sup>1</sup>, De Rosa P<sup>1</sup>, Vallone R<sup>1</sup>, Schettini F<sup>1</sup>, Arpino G<sup>1</sup>, De Placido S<sup>1</sup>, Nazzaro G<sup>1</sup>, Locci M<sup>1</sup>, De Placido G<sup>1</sup>

<sup>1</sup>: University of Naples "Federico II", Naples - Italy.



## Abstract

### Objectives

Breast cancer is one of the most common malignancies in women. Hormonal treatment and chemotherapy induce a transient or permanent menopause status. Vulvovaginal atrophy (VVA) is a frequent debilitating symptom of menopause that is best treated with local or systemic estrogen formulations. Because estrogens drive the growth of the majority of breast cancers, most effective VVA therapies are precluded. The aim of this study was to evaluate the effects of fractional microablative CO<sub>2</sub> laser on sexual function and in relieving symptoms in women with breast cancer and VVA induced or exacerbated by iatrogenic menopause.

### Methods

This retrospective study included 26 women affected by hormone-receptor positive breast tumors and treated for VVA symptoms with the fractional microablative CO<sub>2</sub> laser system. Every 30 to 40 days, women underwent a cycle of treatment for a total of three cycles. During each cycle, women underwent a gynecological examination and completed visual analog scale questionnaires designed to assess (1) the degree of symptoms and (2) procedure-related discomfort.

### Results

Treatment resulted in a significant regression of VVA symptoms and procedure-related discomfort versus baseline ( $P < 0.001$  in almost all cases). No adverse reactions were observed nor reported by women.

### Conclusions

Fractional microablative CO<sub>2</sub> laser treatment is associated with a significant improvement of VVA symptoms in women affected by hormone-driven breast cancer. This procedure has the advantage of relieving iatrogenic/physiological VVA symptoms without resorting to contraindicated estrogen preparations, which have been the most effective therapy thus far.

Chinese Journal of Clinical Obstetrics and Gynecology – Vol. 17, No. 4, 2016

# The curative effect and feasibility analysis of fractional CO<sub>2</sub> laser in the treatment of vulvovaginal in postmenopausal women

Miao Y<sup>1</sup>, Li J<sup>1</sup>, Wang J<sup>1</sup>

<sup>1</sup>: Peking University People's Hospital, Beijing – China.



## Abstract

### Objective

This prospective study aimed to assess the curative efficacy and feasibility of fractional CO<sub>2</sub> laser in the treatment of vulvo-vaginal atrophy (VVA) in postmenopausal women.

### Methods

30 patients with VVA recruited in this study, fractional CO<sub>2</sub> laser treatment was applied, visual analogue scale (VAS) and vaginal health index score (VHIS) measures were used to assess VVA, and degree of pain before and after the treatment, additionally, satisfaction survey was done post treatment.

### Results

Fractional CO<sub>2</sub> laser treatment was significant improved VVA symptoms (vaginal itching, 6.00±2.60 vs. 1.38±0.97, P<0.001; vaginal dryness 7.04±2.26 vs. 1.88±1.03, P<0.001; vaginal burning, 6.25±2.13 vs. 1.50±0.88, P<0.001; dyspareunia, 7.54±2.54 vs. 2.04±1.15, P<0.001), as well as the VHIS (9.79±2.76 vs. 16.33±2.06, P<0.001). Satisfaction with the laser procedure was reported by 28 women (93.33%) and a minimal discomfort was experienced at the laser application. No adverse events were recorded.

### Conclusions

The fractional CO<sub>2</sub> laser treatment can improve the VVA symptoms in postmenopausal patients with vulvo-vaginal atrophy and was proved to be a simple, outpatient therapy for VVA patients.

Chinese Journal of Clinical Obstetrics and Gynecology – Vol. 17, No. 4, 2016

# The application of fractional CO<sub>2</sub> laser in the treatment of vulvar lichen sclerosis

Li J<sup>1</sup>, Miao Y<sup>1</sup>, Wang J<sup>1</sup>

<sup>1</sup>: Peking University People's Hospital, Beijing – China.



## Abstract

### Objectives

To investigate the efficacy and side effects for fractional CO<sub>2</sub> laser in the treatment of vulvar lichen sclerosis (VLS).

### Methods

31 patients with VLS symptoms were enrolled prospectively from July 2015 to April 2016 in Peking University People's Hospital. The fractional CO<sub>2</sub> laser was used for VLS lesions, a total of 3-5 times, each time per-month. Visual analogue scale (VAS) was assessed the degree of vulvar pruritus, skin chapping, dyspareunia before and after treatment. After the treatment, satisfaction survey was done.

### Results

The rate improvement of VLS symptoms was 90.32% (28/31) with fractional CO<sub>2</sub> laser ( $P < 0.001$ ). Compare with before treatment, there were significant difference in pruritus score at the first and the third after treatment one month ( $8.07 \pm 1.97$  vs.  $3.43 \pm 0.94$  and  $1.93 \pm 0.62$ ,  $P < 0.001$ ), vulvar skin chapping score ( $3.5 \pm 1.79$  vs.  $1.36 \pm 1.22$  and  $0.64 \pm 0.84$ ,  $P < 0.005$ ), respectively. The dyspareunia score ( $4.29 \pm 2.70$  vs.  $1.14 \pm 0.95$ ,  $P < 0.05$ ) were improved significantly at the third after treatment one month. After treatment 48h, there were 2 cases with mild pain, 6 cases with local mils hyperemia, 4 cases with mild swelling. No adverse events due to fractional CO<sub>2</sub> laser treatment occurred. During 3-7 months follow-up, 4 cases (12.9%) with the skin color from white to gray, 2 cases recovered sex from 6 cases. The overall satisfaction rate was 96.77% (30/31).

### Conclusions

The fractional CO<sub>2</sub> laser is effective, minimal injury and acceptable side effects for vulvar lichen sclerosis, and may be a new treatment for it.



Maturitas - Vol. 94, 2016. Epub 2016 Sep 16

# Microablative fractional CO<sub>2</sub>-laser therapy and the genitourinary syndrome of menopause: An observational study

Pitsouni E<sup>1</sup>, Grigoriadis T<sup>1</sup>, Tsiveleka A<sup>2</sup>, Zacharakis D<sup>1</sup>, Salvatore S<sup>3</sup>, Athanasiou S<sup>1</sup>

1: National and Kapodistrian University of Athens, Athens - Greece.  
2: "Alexandra Hospital", Athens - Greece. 3: San Raffaele Hospital, Milan - Italy.

## Abstract

### Objective

This study aimed to assess the effect of the Microablative Fractional CO<sub>2</sub> Laser (CO<sub>2</sub>-laser) therapy on vaginal pathophysiology and the symptoms of the Genitourinary Syndrome of Menopause (GSM).

### Methods

Postmenopausal women with moderate to severe symptoms of GSM underwent three sessions of CO<sub>2</sub>-laser therapy at monthly intervals. Participants were evaluated at baseline and 4 weeks after the last treatment.

### Main Outcome Measures

The primary outcomes were Vaginal Maturation Value (VMV) and Vaginal Health Index Score (VHIS). Secondary outcomes included symptoms of GSM, Female Sexual Function Index (FSFI), International Consultation on Incontinence Questionnaire of Female Urinary Tract Symptoms (ICIQ-FLUTS) and Urinary Incontinence Short Form (ICIQ-UI SF), Urogenital Distress Inventory (UDI-6) and King's Health Questionnaire (KHQ).

### Results

Fifty-three postmenopausal women completed this study. VMV, VHIS and FSFI increased significantly. Dyspareunia, dryness, burning, itching, dysuria, frequency, urgency, urgency incontinence, stress incontinence and scores on the ICIQ-FLUTS, ICIQ-UI SF, UDI-6 and KHQ decreased significantly. Factors predicting for which women the CO<sub>2</sub>-laser therapy was more effective were not identified.

### Conclusion

This study suggests that intravaginal CO<sub>2</sub>-laser therapy for postmenopausal women with clinical signs and symptoms of GSM may be effective in improving both vaginal pathophysiology and reported symptoms.

# Fractional CO<sub>2</sub> laser treatment of the vestibule for patients with vestibulodynia and genitourinary syndrome of menopause: a pilot study

Murina F<sup>1</sup>, Karram M<sup>2</sup>, Salvatore S<sup>3</sup>, Felice R<sup>1</sup>

1: V. Buzzi Hospital, Milan - Italy. 2: The Christ Hospital, Cincinnati, OH – USA.

3: San Raffaele Hospital, Milan – Italy.



## Abstract

### Introduction

Chronic vulvar pain and burning remains one of the most perplexing problems faced by practicing gynecologists.

### Aim

To evaluate the effectiveness and safety of the application of micro-ablative fractional CO<sub>2</sub> laser to the vulvar vestibule in the management of patients with vulvar pain from vestibulodynia or genitourinary syndrome of menopause.

### Methods

Patients (N = 70) underwent fractional micro-ablative CO<sub>2</sub> laser treatment for vestibular pain plus vestibulodynia (n = 37) or genitourinary syndrome of menopause (n = 33). Inclusion criteria were the existence of vestibular atrophic changes and the absence of moderate or severe pelvic floor hypertonic dysfunction.

### Main Outcome Measures

A visual analog scale of pain and the Marinoff score of dyspareunia were chosen to evaluate improvement. Grading of vestibular health also was quantified using a four-point scoring system (0 = no atrophy, 3 = severe atrophy). Data were collected at baseline, at weeks 4, 8, and 12, and 4 months after the final treatment.

### Results

For visual analog scale and dyspareunia scoring and for the overall vestibular health index scoring, statistically significant improvement was noted after three sessions of vestibular fractional CO<sub>2</sub> laser treatment. Improvement gradually increased throughout the study period and was maintained through the 4-month follow-up visit. There was no statistically significant difference in outcomes between the two study groups. No adverse events from fractional CO<sub>2</sub> laser treatment were noted. Overall, 67.6% of patients stated significant improvement from the laser procedure.

### Conclusion

This preliminary case series showed encouraging results using fractional CO<sub>2</sub> laser treatment of the vestibule in women with vestibulodynia and genitourinary syndrome of menopause.

Journal of Gynecologic Surgery – Vol. 32, No. 6, 2016. Epub 2016 Nov 21

# Fractional CO<sub>2</sub> laser treatment for vaginal atrophy and vulvar lichen sclerosis

Baggish M S<sup>1</sup>

<sup>1</sup>: University of California, San Francisco, CA – USA.



## Abstract

### Objectives

The aim of this research was to assess the efficacy of fractional CO<sub>2</sub> laser energy for treating vaginal atrophy and lichen sclerosis.

### Materials and Methods

The first study population was 23 postmenopausal women diagnosed with vaginal atrophy via microscopic evaluation and who were symptomatic. The second study population was 27 postmenopausal women diagnosed with lichen sclerosis by biopsy and who were symptomatic. Patients with vaginal atrophy had 3 treatment sessions spaced at 4–6 weeks between each session. Laser settings for this group were: power: Watts, 30; time, 1000 microseconds; and spacing, 1000 micrometers. For the lichen sclerosis group, the power was set at 20 Watts and 3–4 treatments were given at 4–6-week intervals.

### Results

In the vaginal atrophy cohort, 22/23 women who previously complained of dryness and discomfort had these symptoms alleviated and vaginal microscopic exam showed significant changes in color, elasticity, and wetness following 3 courses of CO<sub>2</sub> laser fractional treatment; additionally 20/23 women had elimination of urinary frequency and urgency, 18/21 women had alleviation of dyspareunia. In the lichen sclerosis cohort 24/27 patients who had laser treatment reported cessation of itching and pain/discomfort; and 26/27 women demonstrated visible improvement of skin color, elasticity, vascularity following 3-4 laser treatments. All examinations were performed with the operating microscope.

### Conclusions

The fractional CO<sub>2</sub> laser beam is useful for treating vaginal atrophy and lichen sclerosis. This new technique represents a significant divergence from estrogenic-, steroid- and corticosteroid-bulwark dependence. All treatments were performed in an office setting and were associated with either no pain or, at the most, minimal and temporary discomfort. This new use of the CO<sub>2</sub> laser is an excellent alternative for managing these two troublesome problems, particularly in postmenopausal women.

# Fractional CO<sub>2</sub> laser treatment: a novel approach for stress urinary incontinence management in post-menopausal women

González Isaza P<sup>1</sup>, Ruiz Rosas A I<sup>2</sup>, Vélez Rizo D L<sup>3</sup>

1: Universidad Militar de Colombia, Bogotá – Colombia. 2: Universidad Nacional de Colombia, Bogotá – Colombia.

3: Universidad de la Sabana, Bogotá – Colombia.



## Abstract

### Objective

To describe the results of the fractional CO<sub>2</sub> laser as an alternative treatment for stress urinary incontinence in post-menopausal women, and to demonstrate an improvement in quality of life after the treatment.

### Materials and Methods

A prospective, single centre descriptive study was conducted on 10 post-menopausal patients with diagnosis of stress urinary incontinence. Recruited patients were evaluated with Stress Cough test and urethral Mobility Q-Tip Test, which confirmed the diagnosis. They then began a 3 session treatment protocol; 1 every 3 weeks using the SmartXide<sup>2</sup> V<sup>2</sup>LR fractional microablative CO<sub>2</sub> laser system for the MonaLisa Touch™ procedure in the urethrovesical junction. The Urogenital Distress Inventory UDI-6 was performed to evaluate severity and quality of life impact related to stress urinary incontinence in the patients included in the study, before and after treatment. Patients were monitored from July to December 2013.

### Results

Analysis of the UDI-6 Scores before and at the end of treatment showed an improvement in the score in comparison to the baseline condition, indicating a subjective improvement in all the symptoms related to SUI included in the score.

### Conclusions

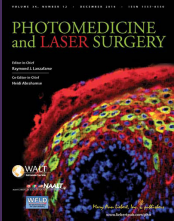
The MonaLisa Touch™ procedure performed with SmartXide<sup>2</sup> V<sup>2</sup>LR laser system is a complementary alternative to traditional surgical techniques, providing a safe and effective treatment for urinary incontinence in post-menopausal women.

Photomedicine and Laser Surgery. – Vol. 35, No. 3, 2017.  
Epub 2016 Dec 30– Vol. 26, No. 1, 2017. Epub 2016 Oct 09

# Fractional CO<sub>2</sub> laser: from skin rejuvenation to vulvo-vaginal reshaping

Filippini M<sup>1</sup>, Del Duca E<sup>2</sup>, Negosanti F<sup>2,3</sup>, Bonciani D<sup>4</sup>, Negosanti L<sup>5</sup>,  
Sannino M<sup>2</sup>, Cannarozzo G<sup>2</sup>, Nisticò SP<sup>2,6</sup>

1: Hospital State of Republic of San Marino - Republic of San Marino. 2: University of Rome Tor Vergata, Rome - Italy.  
3: Dermatology Center, Bologna - Italy. 4: Piero Palagi University Hospital, Florence - Italy.  
5: S.Orsola-Malpighi University Hospital, Bologna - Italy. 6: Magna Grecia University of Catanzaro - Italy .



## Abstract

### Background

The CO<sub>2</sub> laser has become the gold standard treatment in dermatologic surgery for the treatment of a large number of skin and mucosal lesions. The introduction of the fractional micro-ablative technology represented an integration to the ablative resurfacing technique, reducing the healing time and the side effects.

### Objective

Vaginal rejuvenation performed with this technique is a minimally invasive procedure that stimulates internal tissues of the female lower genital tract to regenerate the mucosa, improving tissue trophism and restoring the correct functionality.

### Methods

In our experience, 386 menopausal women affected with vulvo-vaginal atrophy (VVA) were treated with three section of fractional micro-ablative CO<sub>2</sub> laser.

### Results

After three treatments, patients reported a complete improvement of the symptoms (59.94% dryness, 56.26% burn, sensation, 48.75% dyspareunia, 56.37% itch, 73.15% soreness, and 48.79% vaginal introitus pain).

### Conclusions

Fractional micro-ablative CO<sub>2</sub> laser seems to reduce symptoms related to vaginal atrophy. The beneficial effects were reported just after the first session and confirmed 12 months after the last session.



Menopause. Epub 2017 Feb 6

# Use of a novel fractional CO<sub>2</sub> laser for the treatment of genitourinary syndrome of menopause: 1-year outcomes

Sokol ER<sup>1</sup>, Karram MM<sup>2</sup>

1: Stanford University, Stanford, CA - USA. 2: The Christ Hospital, Cincinnati, OH - USA.



## Abstract

### Objectives

To assess safety and efficacy of a fractional CO<sub>2</sub> laser therapy for the treatment of genitourinary syndrome of menopause (GSM) with follow-up to 1 year posttreatment.

### Methods

Women presenting with GSM and meeting inclusion criterion were enrolled. Visual Analog Scales were used to grade vaginal pain, burning, itching, dryness, dyspareunia, and dysuria. Dilators were used to rate vaginal elasticity at baseline and at each follow-up visit. Before each treatment and at follow-up, Vaginal Health Index scoring and Female Sexual Function Index questionnaires were completed. Women received three vaginal laser treatments spaced 6 weeks apart. Participant satisfaction was measured on 5-point Likert scales (1=very dissatisfied, 5=very satisfied).

### Results

Of 30 women (mean age 58.6±8.8 years), three were lost to follow-up at 3 months and six at 1 year. None were discontinued or withdrew due to an adverse event. Average improvement in Visual Analog Scale scores for all symptom categories was statistically significant at 3 months and remained so through 1 year, except dysuria. Differences between data at 3 months and 1 year were not statistically significant, indicating persistence of positive outcomes. Average overall improvement in pain was 1.9 (±3.4), burning 1.9 (±3.1), itching 1.4 (±1.9), dryness 5.9 (±2.8), dyspareunia 4.9 (±3.3), and dysuria 0.9 (±3.1). Improvement in average Vaginal Health Index and Female Sexual Function Index scores was also statistically significant ( $P<0.0001$ ). Of 19 women undergoing dilator examination at 1 year, 18 (94.8%) were comfortable with the same or larger dilator size. Twenty-two of 24 women (92%) were satisfied or extremely satisfied with the treatment at 1 year.

### Conclusions

Based on study data up to 1 year, the fractional CO<sub>2</sub> laser may be an effective and safe treatment for women suffering from symptoms of GSM, although additional studies with larger populations and placebo control is needed to confirm these results.

# Safety and long-term efficacy of fractional CO<sub>2</sub> laser treatment in women suffering from genitourinary syndrome of menopause

Behnia-Willison F<sup>1,2</sup>, Sarraf S<sup>3</sup>, Miller J<sup>4</sup>, Mohamadi B<sup>1</sup>, Care A S<sup>4,5</sup>,  
Lam A<sup>6</sup>, Willison N<sup>2</sup>, Behnia L<sup>7</sup>, Salvatore S<sup>8</sup>

1: FBW Gynaecology Plus - Australia. 2: Flinders University - Australia. 3: Virginia Women's Center - USA.  
4: The University of Adelaide - Australia. 5: Robinson Research Institute - Australia.

6: Centre for Advanced Reproductive Endosurgery - Australia. 7: University of Tehran - Iran. 8: San Raffaele Hospital - Italy.



## Abstract

### Objective

To evaluate the safety and long-term efficacy of fractional CO<sub>2</sub> laser treatment in reducing the severity of symptoms of genitourinary syndrome of menopause (GSM) in menopausal women.

### Study Design

102 women presenting with symptomatic GSM were treated with the fractional CO<sub>2</sub> laser (MonaLisa Touch, DEKA) system across a series of treatments delivered at intervals of six or more weeks. The Australian Pelvic Floor Questionnaire was used to gather data on sexual function and side-effects at three time-points across the study period (prospective panel design study). Wilcoxon signed-rank tests were used to detect statistically and clinically significant changes in sexual function and side-effects occurring from pre- to post-treatment. The primary outcome of this study was an improvement of the symptoms of GSM. The secondary outcome included bladder function and prolapse symptoms.

### Results

A total of 102 women suffering from moderate to severe GSM were recruited. Eighty-four percent experienced significant improvement in their symptoms after CO<sub>2</sub> laser treatment. Scores on measures of sexual function, dyspareunia, and bothersomeness of sexual issues were improved from pre-treatment to long-term (12–24 month) follow-up. Furthermore, there were improvements on measures of bladder function (P = 0.001), prolapse (P = 0.001), vaginal sensation (P = 0.001), vaginal lubrication (P < 0.001) and urge incontinence (P = 0.003) from the pre-treatment assessment to the second assessment (i.e. after the third treatment).

### Conclusions


In this study, fractional microablative CO<sub>2</sub> laser treatment was associated with an improvement in symptoms of GSM and sexual function.

Climacteric – Epub 2017 May 15

# Fractional CO<sub>2</sub> laser therapy: a new challenge for vulvovaginal atrophy in postmenopausal women

Siliquini GP<sup>1</sup>, Tuninetti V<sup>2</sup>, Bounous VE<sup>2</sup>, Bert F<sup>3</sup>, Biglia N<sup>2</sup>

1: Sedes Sapientiae Institute, Turin - Italy. 2: Umberto I Hospital, University of Turin, Turin - Italy. 3: University of Turin, Turin - Italy.



## Abstract

### Objectives

To evaluate the effects of CO<sub>2</sub> laser in the treatment of vulvovaginal atrophy (VA) in postmenopausal women.

### Methods

VVA was assessed in 87 postmenopausal women (mean age 58.6±6.9 years) before and after the treatment. The protocol consisted of three monthly treatments and included the treatment of vulva. Subjective measures included VAS (Visual Analog Scale) both for vaginal dryness and dyspareunia; DIVA (Day-by-day Impact of Vaginal Aging); a questionnaire on treatment satisfaction and one about the degree of pain during the procedure. Objective measures included VHI (Vaginal Health Index) and VVHI (Vulvo-Vaginal Health Index). Time points of the study were at the screening visit (T0), at baseline (T1), at week 4 (T2), at week 8 (T3), after 3 months since the last laser application (T4), after 6 months (T5), after 9 months (T6), after 12 months (T7) and after 15 months (T8).

### Results

Treatment induced significant improvement in the VAS score. After treatment, VHI and VVHI indicated no VVA and this improvement was long lasting. Multivariate analysis showed that the time of follow-up was correlated with better VHI and VVHI ( $p < 0.001$ ). DIVA improved over time ( $p < 0.001$ ).

### Conclusions

This study shows that CO<sub>2</sub> laser treatment induces a significant and long-lasting improvement of symptoms.

International Urogynecology Journal - Epub 2017 May 18

# Long-term effect of thermoablative fractional CO<sub>2</sub> laser treatment as a novel approach to urinary incontinence management in women with genitourinary syndrome of menopause

González Isaza P<sup>1</sup>, Jaguszewska K<sup>2,3</sup>, Cardona JL<sup>4</sup>, Lukaszuk M<sup>3</sup>

1: San Jorge University Hospital, Pereira - Colombia. 2: Medical University of Gdansk, Gdansk - Poland. 3: Medical Centre Nowe Orlowo, Gdynia - Poland. 4: Technological University of Pereira, Pereira - Colombia.



## Abstract

### Introduction and Hypothesis

The aim of this study was to evaluate the long-term effect of thermoablative fractional CO<sub>2</sub> laser (TACO2L) as an alternative treatment for early stages of stress urinary incontinence (SUI) in postmenopausal women with genitourinary syndrome of menopause.

### Methods

A total of 161 postmenopausal patients (age 53.38 ± 5.1 years, range 45-65 years) with a clinical diagnosis of mild SUI were prospectively enrolled in the study. Patients received one treatment with TACO2L every 30-45 days, each treatment comprising four sessions, followed in all patients by a yearly treatment session at 12, 24 and 36 months. SUI was evaluated using the International Continence Society 1-h pad test and the International Consultation on Incontinence Questionnaire-Urinary Incontinence Short Form (ICIQ-UI SF) before and after TACO2L treatment.

### Results

TACO2L treatment was associated with a significant improvement in ICIQ-UI SF scores and 1-h pad weight test at 12 months (both  $p < 0.001$ ), 24 months (both  $p < 0.001$ ) and 36 months (both  $p < 0.001$ ). Improvements were maintained for up to 36 months without the need for any further intervention. The results were confirmed by significant histological changes related to trophic restoration of the vagina, responsible for extrinsic and intrinsic mechanisms involved in urinary continence.

### Conclusions

Our results suggest that TACO2L is an efficient and safe novel treatment strategy in patients with mild SUI. Further investigation to confirm the long-term results presented here is still warranted.

Maturitas - Epub 2017 June 27

# Laser therapy for the genitourinary syndrome of menopause. A systematic review and meta-analysis

Pitsouni E<sup>1</sup>, Grigoriadis T<sup>1</sup>, Falagas M<sup>2,3</sup>, Salvatore S<sup>4</sup>, Athanasiou S<sup>1</sup>

1: Alexandra Hospital, National and Kapodistrian University of Athens, Greece.

2: Alfa Institute of Biomedical Sciences (AIBS), Athens – Greece. Henry-Dunant Hospital Center, Athens – Greece.

3: Tufts University School of Medicine, Boston, MA – USA. 4: San Raffaele Hospital, Milan – Italy.



## Abstract

This study aimed to identify and then synthesize all available data regarding the efficacy of laser therapy for postmenopausal women with genitourinary syndrome of menopause (GSM) with/without urinary incontinence (UI). PubMed, Scopus, Web of Science, Cochrane Library and ClinicalTrials.gov were searched in October 2016. The keywords were “laser genitourinary syndrome of menopause”, “laser vulvovaginal atrophy”, “laser vaginal atrophy” and “laser women incontinence”.

Quality of reporting and risk of bias of the included studies were assessed according to STROBE and MINORs checklists, respectively. Quality of the body of evidence was evaluated with the GRADE approach.

Fourteen studies involving 542 participants were included in this systematic review and meta-analysis. All GSM symptoms (dryness/dyspareunia/itching/burning/dysuria/urgency/frequency) and UI decreased significantly and consistently in all available publications. The pooled mean differences for the various symptoms were: dryness  $-5.5$  (95%CI:  $-6.7, -4.4$ ; 7 studies; I<sup>2</sup>:0%), dyspareunia  $-5.6$  (95%CI:  $-6.8, -4.5$ ; 7 studies; I<sup>2</sup>:0%), itching  $-4$  (95%CI:  $-5.7, -2.2$ ; 6 studies; I<sup>2</sup>:79%), burning  $-3.9$  (95%CI:  $-5.9, -2.6$  studies; I<sup>2</sup>:87%), dysuria  $-2.9$  (95%CI:  $-5.1, -0.7$ ; 4 studies; I<sup>2</sup>:90%) and UI  $-4.9$  (95%CI:  $-6.4, -3.4$ ; 2 studies; I<sup>2</sup>:0%). Because urgency/frequency was assessed by different methodologies the data could not be meta-analyzed. Furthermore, KHQ, UDI-6, MCS12/PCS12, FSFI, overall sexual satisfaction and measurements of the effect of laser therapy on the local pathophysiology improved significantly.

In conclusion, laser therapy for postmenopausal women with GSM appears promising. It may reduce symptom severity, improve quality of life of postmenopausal women and restore the vaginal mucosa to premenopausal status. However, the quality of the body of evidence is “low” or “very low” and, thus, evidence-based modification of current clinical practice cannot be suggested.

# CO<sub>2</sub>-laser for the genitourinary syndrome of menopause. How many laser sessions?

Athanasίου S<sup>1</sup>, Pitsouni E<sup>1</sup>, Falagas ME<sup>2,3</sup>, Salvatore S<sup>4</sup>, Grigoriadis T<sup>1</sup>

<sup>1</sup>: Alexandra Hospital, National and Kapodistrian University of Athens, Greece.

<sup>2</sup>: Alfa Institute of Biomedical Sciences (AIBS), Athens – Greece. Henry-Dunant Hospital Center, Athens – Greece.

<sup>3</sup>: Tufts University School of Medicine, Boston, MA –USA. <sup>4</sup>: San Raffaele Hospital, Milan – Italy.



## Abstract

### Objectives

The aim of this prospective study was to assess the efficacy of 3, 4 or 5 CO<sub>2</sub>-laser sessions for the management of the genitourinary syndrome of menopause (GSM).

### Methods

Postmenopausal women with moderate to severe symptoms of dyspareunia, wanting to resume/retain sexual activity, were treated with 3–5 laser sessions depending on symptom severity/presence, sexual function, clinical findings and women's preference following the third laser application.

### Main Outcomes

Severity of dyspareunia, dryness, sexual function, sexual satisfaction and frequency of sexual intercourse defined the primary outcomes. Vaginal Maturation Value (VMV) and Vaginal Health Index Score (VHIS) defined the secondary ones.

### Results

Fifty-five women received three sessions, 53 an extra fourth and 22 an extra fifth. Following the third, fourth and fifth laser sessions, respectively: dyspareunia completely regressed in 15/55 (27%), 32/55 (58%) and 38/47 (81%) of participants; dryness completely regressed in 20/55 (36%), 36/55 (66%) and 44/51 (86%); normal sexual function resumed in 23/55 (41%), 37/54 (69%) and 41/49 (84%); VMV regained non-atrophic values in 29/55 (53%), 38/55 (69%) and 42/50 (84%); and VHIS regained non-atrophic values in 44/55 (80%), 53/55 (96%) and 55/55 (100%) of participants.

### Conclusion


Results of this study indicate that CO<sub>2</sub>-laser therapy may contribute to complete regression of dyspareunia and dryness and reestablishment of normal sexual function in postmenopausal women, in a dose-response manner. An extra fourth or fifth session may further increase the GSM symptom-free rate.

Current Opinion in Obstetrics and Gynecology – Epub 2017 Jul 29

# Lasers for pelvic floor dysfunctions: is there evidence?

Lang P, Karram M

The Christ Hospital, Cincinnati, OH - USA.



## Abstract

### Purpose of Review

The purpose of this review is to discuss the available energy sources used in the vaginal canal that are currently being promoted for certain pelvic floor conditions and explore the body of peer-reviewed literature supporting their use.

### Recent Findings

The majority of research has focused on the use of fractional CO<sub>2</sub> laser treatment for genitourinary syndrome of menopause (GSM). Most of these studies are nonrandomized prospective studies, but their data consistently shows an improvement in symptoms without significant side effects.

### Summary

Vaginal laser treatment for GSM is of particular interest to gynecologists as it provides patients with a history of estrogen receptor positive breast cancer, thromboembolic event, or other contraindication to hormone therapy, an effective treatment option. Currently, we are in the early stages of scientific investigation into the use of lasers in the treatment of pelvic floor dysfunction, but the emerging data is encouraging. The existing data is limited to mostly observational studies with additional quality randomized controlled trials and sham studies needed to ensure that physicians are providing the optimum evidence-based treatments to their patients. At the present time there is insufficient data to promote these therapies for stress incontinence, vaginal tightening, or other pelvic floor abnormalities.

# Randomized, double-blind, placebo-controlled clinical trial for evaluating the efficacy of fractional CO<sub>2</sub> laser compared with topical estriol in the treatment of vaginal atrophy in postmenopausal women

Cruz VL, Steiner ML, Pompei LM, Strufaldi R,

Fonseca FLA, Santiago LHS, Wajsfeld T, Fernandes CE

ABC School of Medicine, São Bernardo do Campo, São Paulo – Brazil.



## Abstract

### Objective

The aim of the study was to evaluate efficacy of fractional CO<sub>2</sub> vaginal laser treatment (Laser, L) and compare it to local estrogen therapy (Estriol, E) and the combination of both treatments (Laser + Estriol, LE) in the treatment of vulvovaginal atrophy (VVA).

### Methods

A total of 45 postmenopausal women meeting inclusion criteria were randomized in L, E, or LE groups. Assessments at baseline, 8 and 20 weeks, were conducted using Vaginal Health Index (VHI), Visual Analog Scale for VVA symptoms (dyspareunia, dryness, and burning), Female Sexual Function Index, and maturation value (MV) of Meisels.

### Results

Forty-five women were included and 3 women were lost to follow-up. VHI average score was significantly higher at weeks 8 and 20 in all study arms. At week 20, the LE arm also showed incremental improvement of VHI score (P=0.01). L and LE groups showed a significant improvement of dyspareunia, burning, and dryness, and the E arm only of dryness (P<0.001). LE group presented significant improvement of total Female Sex Function Index (FSFI) score (P=0.02) and individual domains of pain, desire, and lubrication. In contrast, the L group showed significant worsening of pain domain in FSFI (P=0.04), but FSFI total scores were comparable in all treatment arms at week 20.

### Conclusions

CO<sub>2</sub> vaginal laser alone or in combination with topical estriol is a good treatment option for VVA symptoms. Sexual-related pain with vaginal laser treatment might be of concern.




# Microablative fractional CO<sub>2</sub> laser for the genitourinary syndrome of menopause: power of 30 or 40 W?

Pitsouni E<sup>1</sup>, Grigoriadis T<sup>1</sup>, Falagas M<sup>2,3</sup>, Tsiveleka A<sup>1</sup>, Salvatore S<sup>4</sup>, Athanasiou S<sup>1</sup>

1: Alexandra Hospital, National and Kapodistrian University of Athens, Greece.

2: Alfa Institute of Biomedical Sciences (AIBS), Athens – Greece. Henry-Dunant Hospital Center, Athens – Greece.

3: Tufts University School of Medicine, Boston, MA –USA. 4: San Raffaele Hospital, Milan – Italy.



## Abstract

This retrospective case-control study aimed to compare 30 versus 40 W power of CO<sub>2</sub> laser for the therapy of genitourinary syndrome of menopause (GSM). Postmenopausal women with severe intensity of dyspareunia and dryness were eligible to be included in this study. Primary outcomes were dyspareunia and dryness. Secondary outcomes were itching/burning, dysuria, frequency and urgency, Female Sexual Function Index (FSFI), vaginal maturation value (VMV), and Vaginal Health Index Score (VHIS).

One laser therapy was applied every month for 3 months. Outcomes were evaluated at baseline and 1 month following the 3rd therapy. Fifty (25 per group) women were included in this study. In the 30-W group, mean improvement of dyspareunia, dryness, itching/burning, FSFI, VMV, and VHIS was  $6.1 \pm 1.7$ ,  $6.0 \pm 1.9$ ,  $5.9 \pm 2.0$ ,  $16.6 \pm 6.7$ ,  $29.9 \pm 13.0$ , and  $11.0 \pm 2.9$ , respectively (within group comparisons all  $p < 0.001$ ). In the 40-W group, mean improvement of dyspareunia, dryness, itching/burning, FSFI, VMV, and VHIS was  $6.1 \pm 1.7$ ,  $6.5 \pm 2.0$ ,  $5.2 \pm 2.5$ ,  $14.8 \pm 7.1$ ,  $25.0 \pm 13.4$ , and  $10.5 \pm 4.1$ , respectively (within-group comparisons, all  $p \leq 0.001$ ).

Comparison between 30 and 40 W revealed that mean improvement or presence of all GSM symptoms and clinical signs was not statistically significant different. CO<sub>2</sub> laser therapy may improve GSM symptoms and clinical signs. This improvement did not seem to associate to power of 30 or 40 W.

# Sexual function in women suffering from genitourinary syndrome of menopause treated with fractionated CO<sub>2</sub> laser

Salvatore S<sup>1</sup>, Pitsouni E<sup>2</sup>, Del Deo F<sup>1</sup>, Parma M<sup>1</sup>, Athanasiou S<sup>2</sup>, Candiani M<sup>1</sup>.

1: Tufts University School of Medicine, Boston, MA –USA, 4: San Raffaele Hospital, Milan – Italy, 2: Alexandra Hospital, National and Kapodistrian University of Athens, Greece



## Abstract

### Introduction

Genitourinary syndrome of menopause (GSM) has a significant impact on the trophism of the genital and lower urinary tracts and can considerably impair sexual function. Fractional CO<sub>2</sub> laser has a regenerative effect on vulvovaginal tissue trophism after menopause.

### Aim

To review the available literature on the effect of fractional CO<sub>2</sub> laser on the sexual function of postmenopausal women affected by GSM.

### Methods

A database search was carried out using the terms CO<sub>2</sub> laser, vaginal atrophy, sexual function, dyspareunia, and genitourinary syndrome of menopause and excluding studies using other types of laser or including breast cancer survivors with vulvovaginal atrophy. For statistical analysis, the estimated overall laser effect was computed (when at least two studies were involved) and data type of generic inverse variance was computed using inverse variance as the statistical method, a random-effects model, and the difference in means as an effect measurement.

### Main Outcome Measures

Different methods of evaluating sexual function were reported and studies were grouped and analyzed accordingly. Subjective assessment for dyspareunia was evaluated with a 10-point visual analog scale. Patient-reported outcome for an overall perception of sexual function was evaluated with a Likert scale. The Female Sexual Function Index was used as a condition-specific questionnaire.

### Results

Six articles were considered for this review. A total of 273 women (mean age = 57.8 years) were treated with the same protocol in all studies. Compared with baseline, at the end of the treatment, dyspareunia significantly decreased in severity ( $P < .001$ ), and the patient's perception of overall sexual function showed a statistically significant improvement ( $P < .001$ ). At the last follow-up visit, the Female Sexual Function Index score for each single domain and overall score was significantly better than at entry ( $P < .001$ ).

### Conclusion

Fractional CO<sub>2</sub> laser can improve sexual function in postmenopausal women affected by GSM by restoring a better trophism in the lower genitourinary tract.

# Long-term reliability of fractioned CO<sub>2</sub> laser as a treatment for vulvovaginal atrophy (VVA) symptoms

Pieralli A<sup>1</sup>, Bianchi C<sup>1</sup>, Longinotti M<sup>1</sup>, Corioni S<sup>1</sup>, Auzzi N<sup>1</sup>, Becorpi A<sup>1</sup>, Fallani MG<sup>1</sup>, Cariti G<sup>1</sup>, Petraglia F<sup>1</sup>

<sup>1</sup>: Careggi University Hospital, Florence - Italy.



## Abstract

### Purpose

The aim of this study was to evaluate long-term effects of the fractional CO<sub>2</sub> laser for the treatment of vulvovaginal atrophy (VVA) symptoms.

### Methods

Women presenting with VVA symptoms and meeting inclusion criterion were enrolled to fractioned CO<sub>2</sub> laser therapy. Patient's satisfaction was measured on five-point Likert scale at 4 weeks and 6, 12, 18, 24 months after treatment by interview and clinical examination for vaginal livability.

### Results

184 patients constituted the final study group: 128 women were spontaneous menopause and 56 were oncological menopause. 117 women were nulliparous and 36 had previous hysterectomy. 95.4% (172/184) of the patients declared that they were satisfied or very satisfied with the procedure at 4 weeks after treatment. At 6 months 92% (170/184) patients were satisfied; at 12 months 72% (118/162) were satisfied; at 18 months 63% (60/94) were satisfied; at 24 months 25% (4/16) of patients answered they were still satisfied. We observed a decline in patient's satisfaction between 18 and 24 months after laser therapy. Data showed that the time interval from onset of menopause was a statistically significant factor ( $p < 0.05$ ) for treatment satisfaction in oncological group.

### Conclusions

Long-term data showed that the improvement of vaginal health may continue up to 24 months after fractional CO<sub>2</sub> laser treatment although between 18 and 24 months benefits decline, and approximately 80% of women decide to start a new treatment cycle of laser applications.

# Fractional CO<sub>2</sub> laser of the vagina for genitourinary syndrome of menopause: Is the out-of-pocket cost worth the outcome of treatment?

Lang P<sup>1</sup>, Dell JR<sup>2</sup>, Rosen L<sup>3</sup>, Weiss P<sup>4</sup>, Karram M<sup>1</sup>.

1: The Christ Hospital, Cincinnati, OH - USA. 2: Institute for Female Pelvic Medicine, Knoxville, TN - USA.  
3: Fairfax OB-GYN Associates, Gainesville, VA - USA. 4: Roxbury Surgical Center, Beverly Hills, CA - USA.



## Abstract

### Objectives

The purpose of this study is to assess patient's satisfaction treatment outcomes and out-of-pocket expense for the fractional CO<sub>2</sub> laser (SmartXide) in the treatment of genitourinary symptoms of menopause (GSM).

### Materials and Methods

A multicenter retrospective cohort study of patients who completed a course of three vaginal treatments with the SmartXide Fractional CO<sub>2</sub> laser. Patients contacted via telephone and asked to participate in questionnaires to evaluate for adverse outcomes since last treatment, symptom severity before and after treatment, patient satisfaction with treatment, patient satisfaction with out-of-pocket expense, and sexual function.

### Results

Of the 368 patients contacted, 122 agreed to be interviewed. No patients reported seeking emergent medical treatment. Patient reported vaginal dryness significantly improved following treatment ( $P < 0.05$ ). The frequency of intercourse increased from "once a month" to "few times a month" ( $P < 0.001$ ). The vast majority of patients reported being satisfied with their treatment results (86%) and with the cost of treatment (78%). Satisfaction with the out-of-pocket expense did not correlate with household income ( $P = 0.07$ ).

### Conclusions

The SmartXide Fractional CO<sub>2</sub> laser is a safe and efficacious treatment for GSM. This treatment is associated with a high level of patient satisfaction with both treatment results and out-of-pocket expense.

## PRESENTATIONS & POSTERS

---

### **An assessment of the safety and efficacy of the SmartXide<sup>2</sup> V<sup>2</sup>LR CO<sub>2</sub> laser for the treatment of vulvovaginal atrophy.**

Sokol E.R., Karram M.

[Poster presented at North American Menopause Society (NAMS) 2015, Annual Meeting - Las Vegas, NE, USA.]

### **Microablative fractional CO<sub>2</sub> laser for vulvovaginal atrophy in women with a history of breast cancer.**

Leone Roberti Maggiore U., Parma M., Candiani M., Salvatore S. Journal of Minimally Invasive Gynecology. 2015 Nov–Dec; 22(6) Supplement: p. S100. doi:10.1016/j.jmig.2015.08.269.

[Abstracts of the 44<sup>th</sup> AAGL Global Congress of Minimally Invasive Gynecology 2015 - Las Vegas, NE, USA]

### **Treatment of coexistent lichen sclerosus and vulvo-vaginal atrophy with fractional CO<sub>2</sub> laser therapy.**

Dell J. Lasers Surg. Med. 2016 April; 48(4):433 #LB39. doi: 10.1002/lsm.22526.

[Late-breaking abstracts for the 36<sup>th</sup> ASLMS 2016 - Annual Conference, Boston, MA, USA]

### **Is it all just smoke and mirrors?: Vaginal laser therapy and its assessment by tactile imaging.**

Van Raalte H., Bhatia N., Egorov V.

[Poster presented at the International Urogynecological Association (IUGA) - 41<sup>th</sup> Annual Meeting, Cape Town, South Africa, 2016]

### **An assessment of the safety and fractional CO<sub>2</sub> laser for the treatment of vulvovaginal atrophy.**

Lang P, Hussain S., Karram M. Lasers Surg. Med. 2016 April; 48(4):433 #LB40. doi: 10.1002/lsm.22526. [Late-breaking abstracts for the 36<sup>th</sup> ASLMS 2016 - Annual Conference, Boston, MA, USA]

## PRESENTATIONS & POSTERS

---

### **Fractional CO<sub>2</sub> laser effect on thick connective tissue of the vaginal wall of women with anterior vaginal prolapse: an ex-vivo study.**

Salvatore S., Virgilio S., Palmieri S. Girardelli S., Redaelli A., Parma M., Candiani M., Calligaro A. European Journal of Obstetrics and Gynecology and Reproductive Biology. 2017 April; Vol. 211:207–8 #18. Doi: <http://dx.doi.org/10.1016/j.ejogrb.2017.01.044>  
[Oral Abstracts, 9<sup>th</sup> EUGA 2016 - Annual Congress, Amsterdam, Netherlands]

### **Effects of fractional microablative CO<sub>2</sub> laser therapy on sexual function in postmenopausal women and women with a history of breast cancer treated with endocrine therapy.**

Gittens, P., Mullen, G. The Journal Of Urology. 2017 April; Vol. 197, No. 4S, Supplement, Page e883. Doi: <https://doi.org/10.1016/j.juro.2017.02.2065>  
[Oral communication, AUA 2017 – Annual Meeting, Boston, MA, USA and also presented as poster at the ISSWSH 2017 - Annual Meeting, Atlanta, GA, USA]

### **Improvement in female sexual function using CO<sub>2</sub> laser therapy.**

Sophocles M., Sadiq F. The Journal of Sexual Medicine. 2017 May. Volume 14, Issue 5, Supplement 4, 2017, e253-e254  
[23<sup>rd</sup> Congress of the World Association for Sexual Health 2017 - Prague, Czech Republic]

### **Improvement in female sexual function using CO<sub>2</sub> laser therapy.**

Sophocles M. The Journal of Sexual Medicine. 2017 June. Volume 14, Issue 6, Supplement 5, e362-e363, #035. Doi: <https://doi.org/10.1016/j.jsxm.2017.04.039>  
[Proceedings of the ISSWSH 2017 - Annual Meeting, Atlanta, GA, USA]

### **Vaginal microbiota in postmenopausal women treated with pulsed CO<sub>2</sub> laser for genitourinary syndrome of menopause (GSM).**

Salvatore S., Verri ., Girardelli S., Iachini E., Mancini N., Marotta E., Candiani M. Maturitas. 2017 June. Volume 100, p:198 #P159. DOI: <https://doi.org/10.1016/j.maturitas.2017.03.259>  
[11<sup>th</sup> Congress of EMAS 2017 - Amsterdam, Netherlands]





The Code of Excellence  
[www.dekalaser.com](http://www.dekalaser.com)