


Summer injuries





Objectives

- To review some injuries in the seasonal context (for today, this will be mostly regarding infectious disease)
- To discuss potential deviation from standard practice in these special scenarios

Disclosures

- None



Case 1



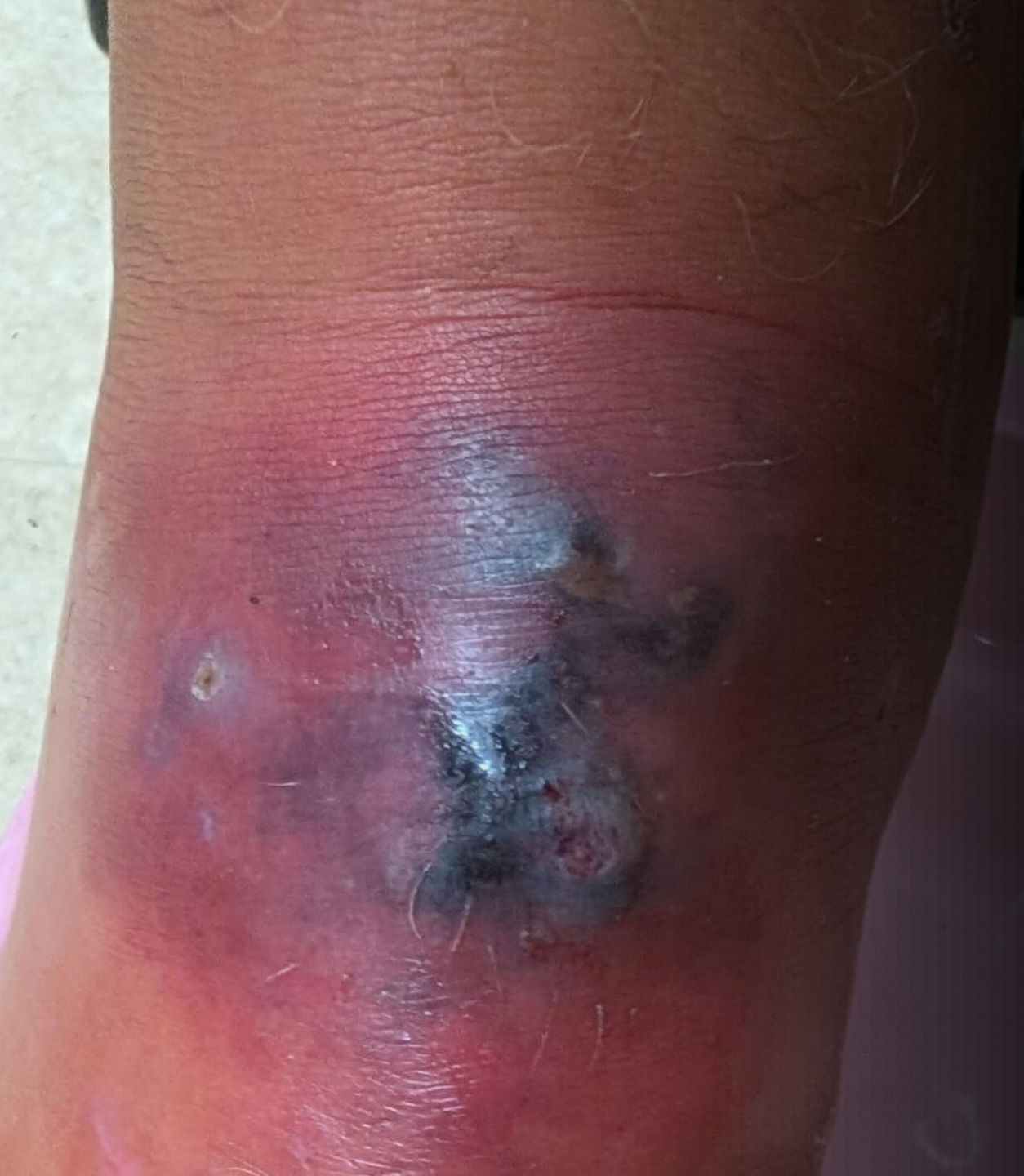17-year-old male with infected foot x 4 days

At family cottage, unsure if he cut his foot somewhere, has continued vacation activities including water sports

Seen by physician 2 days ago, started on Septra, not improving

Systemically well

Healthy, IUTD

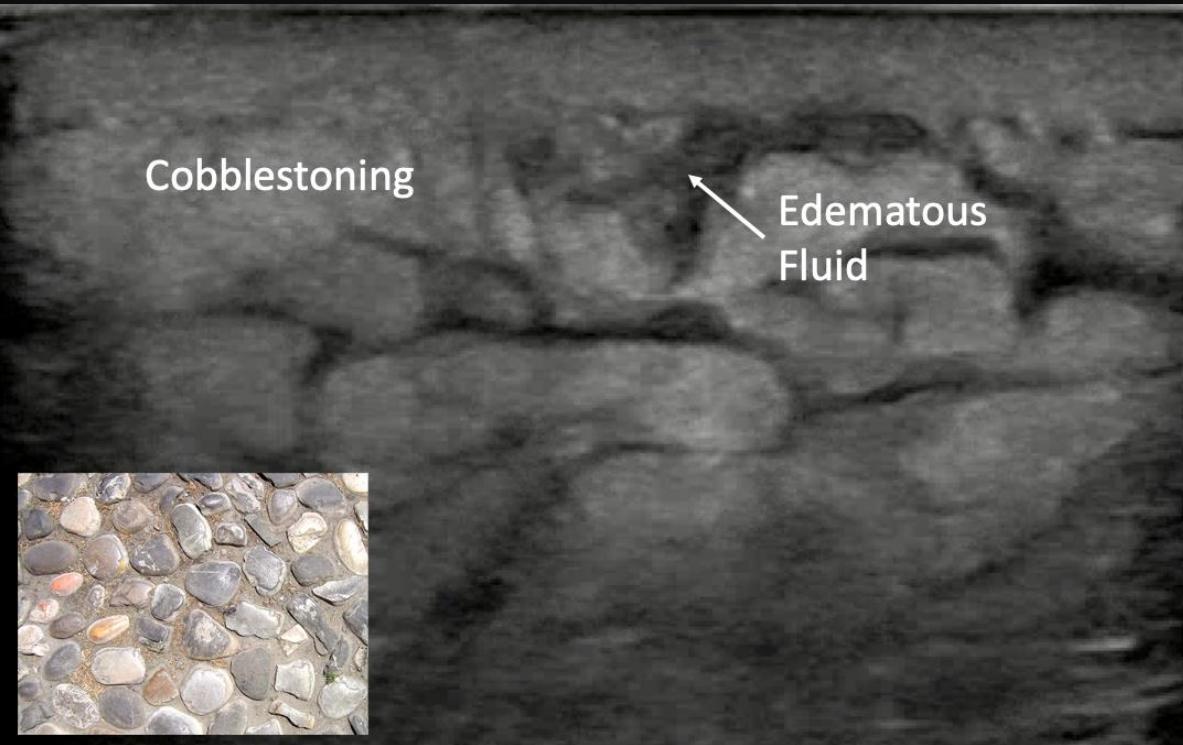


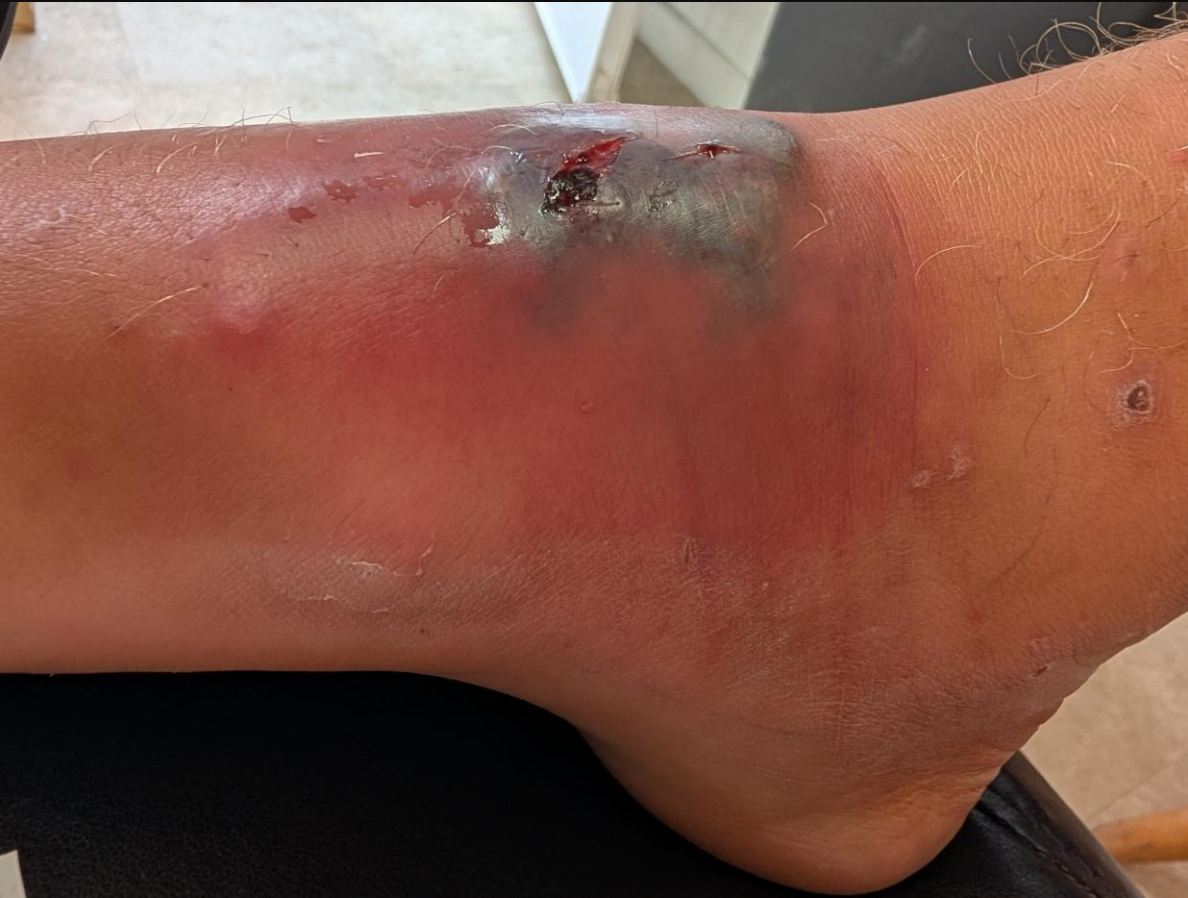On exam

- Vitals N
- No POOP
- Neurovascular status intact

Management

- Unremarkable septic work up
- U/S shows cobble stoning
- Switched to PO keflex





Second presentation

- No improving on keeled after 48 hours, possibly worse
 - Remain systemically well
-

Freshwater cellulitis

Aeromonas hydrophila is the most clinically important for us

- Gram -ve facultative anaerobe
- Likes freshwater environments, particular warm stagnant/slow moving water
- causes a cellulitis that can progress aggressively, sometimes with myonecrosis
- Coverage requires a fluoroquinolone (ciprofloxacin), or a third-generation cephalosporin. (Septra ok but increasing resistance)
- Can mimic clostridial gas gangrene clinically and on imaging

Pseudomonas aeruginosa also relevant

- freshwater exposure
- Particularly relevant especially in immunocompromised patients.

Edwardsiella tarda


- Less common
- Gram -ve
- Bacteremia in immunocompromised hosts

Chromobacterium violaceum

- Rare tropical freshwater
- Rapid progression to fatal septicemia



Takeaway


- When water exposure is involved, consider special coverage if no improvement
 - For us, this usually means gram –ve
 - Consideration RE empiric gram –ve coverage upfront?
 - Gram +ve is still more common, to consider if immunity of concern
- 



Case 2



28 y/o F here due to bite wound



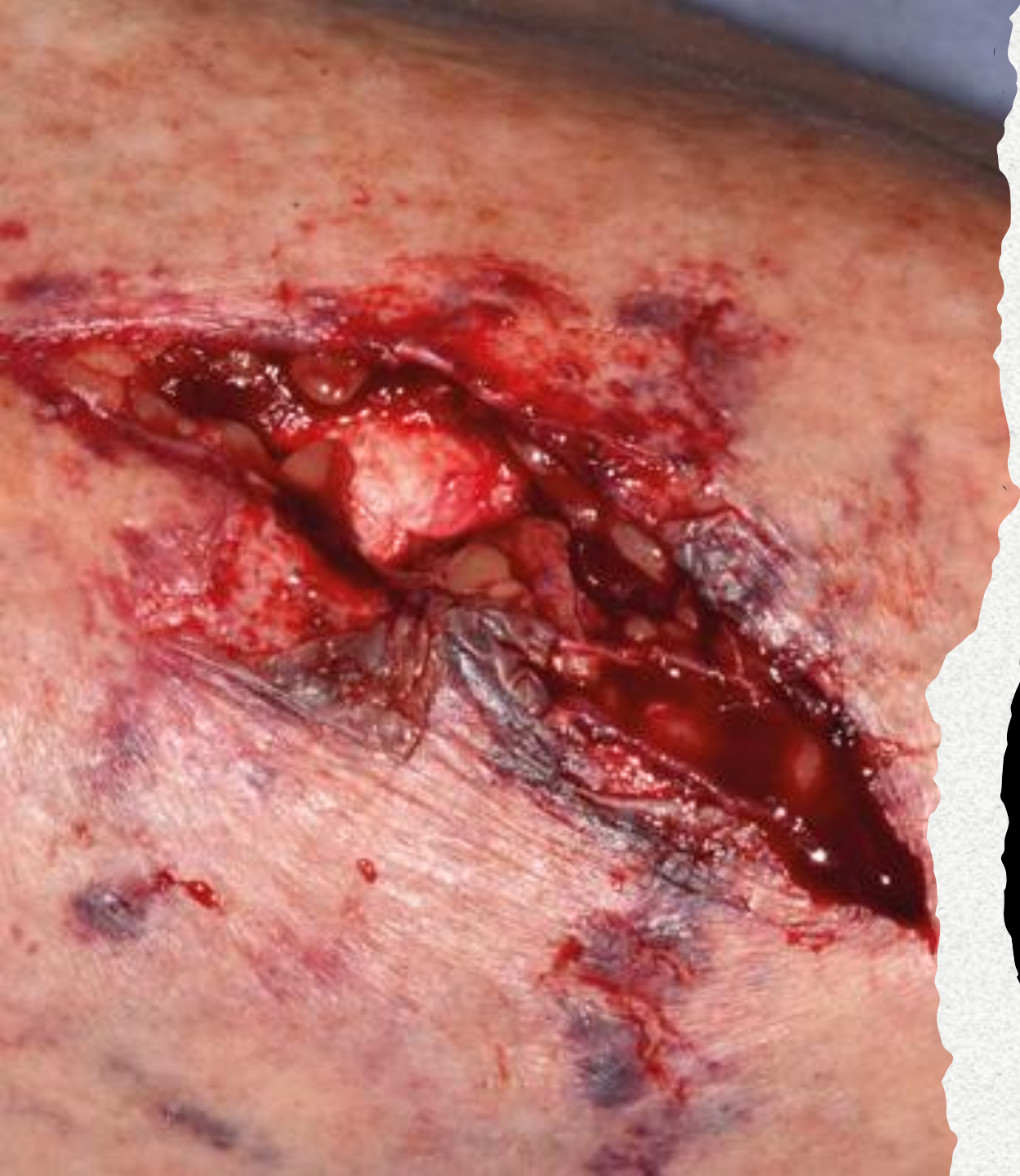Accidentally bitten by a friendly dog from the neighbours while playing tug 6 hours ago



PMHx healthy



Tdap in school, cannot recall



Exam

- Neurovascularly intact
- No obvious tendon injury
- Isolated injury

Wound closure?

- **IDSA recommends against primary closure of none facial bite wounds.** Approximation may be done.
- **However**, evidence exist for closing dog bites on trunk, arms, legs.
 - Similar infection risk as no closure
 - Bites to face also exhibit lower infection risk for both dog & cat bites
- Predictors for low infection risk:
 - Uninfected wound
 - Immunocompetent
 - Recent bite(<12 on extremity, <24 on face)
 - No crush or puncture
 - No prior hx of cellulitis or venous/lymphatic compromise on affected extremity
- If ineligible, empiric abx +/- delayed closure in 3-4 days
- Most wounds that do not develop signs of infection by three days and have no retained foreign body will likely not become infected

Antibiotics?

- Immunocompromised / asplenic
- Advanced liver disease
- preexisting or resultant edema of the affected area
- Moderate to severe injuries, especially to the hand or face
- Injuries that may have penetrated the periosteum or joint capsule

Antibiotic regimen

Empiric coverage of 3 – 5 days is recommended, with coverage for both aerobic and anaerobic organisms

Amoxicillin clavulate preferred

TMPSMX / doxycycline + metronidazole if allergy

Mice and rats consider fluroquinone / doxycycline for tularemia

Other animals?

Human bites are nasty, need empiric coverage

Rodents often requires as well

Farm related injuries consider clostridial contamination, high dose penicillin

Reptiles (snakes, lizards) and insects typically do not require antibiotics, however, produces significant local reaction that might benefit from topical steroids

Consider Lyme in ticks

Tetanus?

- To be updated if not within 10 years
- Tdap recommended over Td
- However, some instances 5 years
 - “dirty” wound -> Feces, soil, or presence of necrotic tissue
- Will also need Tig if never completed series

Tetanus toxoid: Canadian Immunization Guide Government of Canada

Table 1: Guide to tetanus prophylaxis in wound management

History of tetanus immunization	Clean, minor wounds		All other wounds	
	Tetanus toxoid-containing vaccine [*]	T.Ig	Tetanus toxoid-containing vaccine [*]	T.Ig ^{**}
Unknown or less than 3 doses in a vaccine series [†]	Yes	No	Yes	Yes
3 or more doses in a vaccine series and less than 5 years since last booster dose	No	No	No	No [‡]
3 or more doses in a vaccine series and more than 5 years but less than 10 years since last booster dose	No	No	Yes	No [‡]
3 or more doses in a vaccine series and more than 10 years since last booster dose	Yes	No	Yes	No [‡]

^{*} Refer to [Recommendations for Use](#) for specific tetanus toxoid-containing vaccine recommendation based on age.

^{**} Given at different injection sites using separate needles and syringes

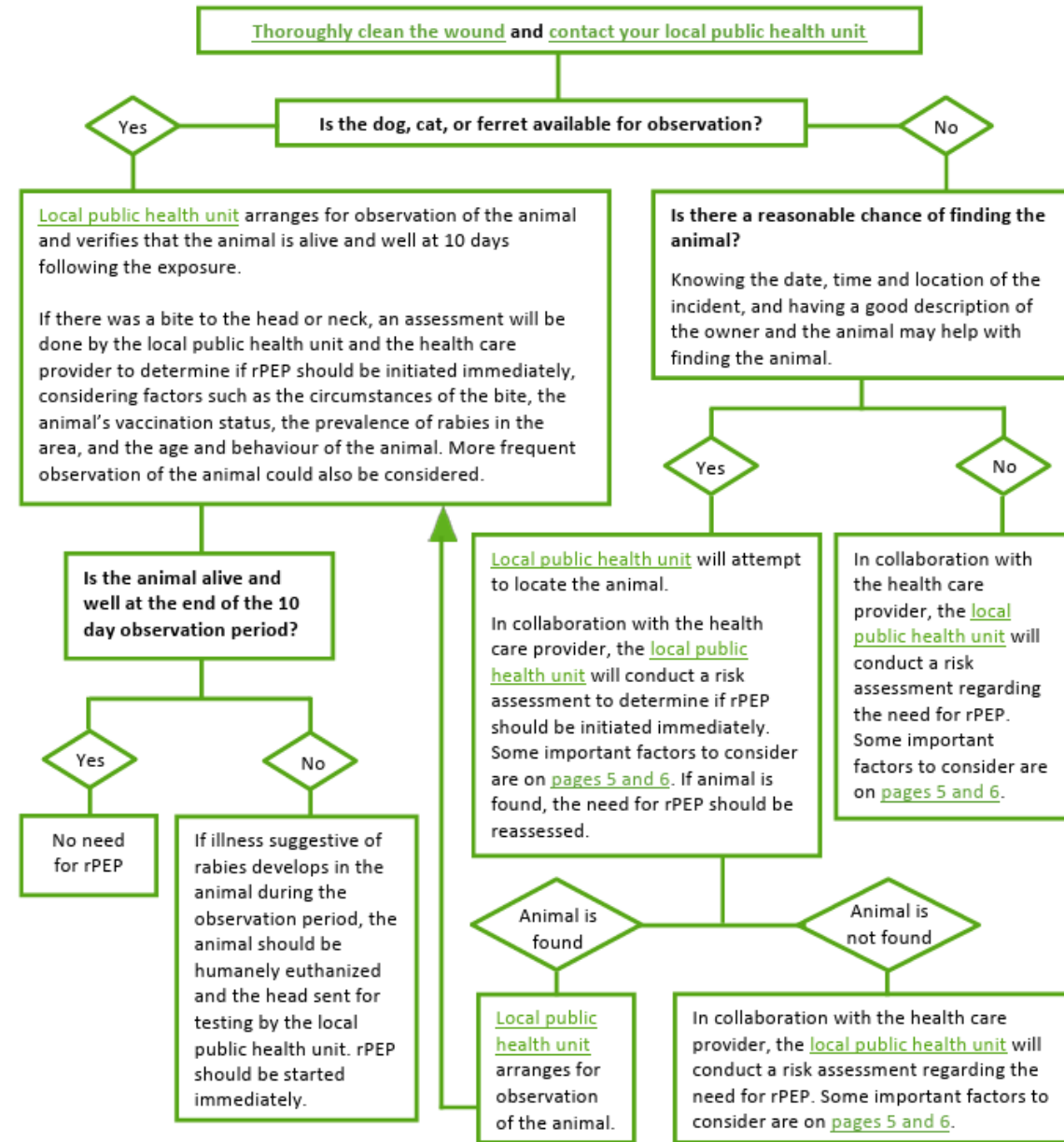
[†] Refer to [Schedule](#)

[‡] Yes, if known to have a humoral immune deficiency state

T.Ig tetanus immunoglobulin

Rabies – Public Health Ontario

*Can contact local health unit for help. Does have Public Health MD on-call who can assist clinical questions



Takeaway

- It is actually evidence based to selectively close some bite wounds, discuss with patient R&B when in doubt reasonable in my opinion
- Delayed closure as a viable option as well
- Antimicrobials, tetanus, rabies, antidote
- Chart / tables available on public health websites
- Public health binder in ED as well with guidelines consolidated
- Consider AI assisted search when rare exposures occur (do verify source)



Thank you

References

- Noonburg GE. Management of extremity trauma and related infections occurring in the aquatic environment. *J Am Acad Orthop Surg*. 2005 Jul-Aug;13(4):243-53. doi: 10.5435/00124635-200507000-00004. PMID: 16112981.
- Post-Travel Dermatologic Conditions. CDC Yellow Book. 2025. Karolyn A. Wanat and Scott A. Norton

References

- Stevens DL, Bisno AL, Chambers HF, Dellinger EP, Goldstein EJ, Gorbach SL, Hirschmann JV, Kaplan SL, Montoya JG, Wade JC. Practice guidelines for the diagnosis and management of skin and soft tissue infections: 2014 update by the infectious diseases society of America. *Clin Infect Dis*. 2014 Jul 15;59(2):147-59. doi: 10.1093/cid/ciu296. Epub 2014 Jun 18. PMID: 24947530.
- Paschos NK, Makris EA, Gantsos A, Georgoulis AD. Primary closure versus non-closure of dog bite wounds. a randomised controlled trial. *Injury*. 2014 Jan;45(1):237-40. doi: 10.1016/j.injury.2013.07.010. Epub 2013 Aug 2. PMID: 23916901.
- Maimaris C, Quinton DN. Dog-bite lacerations: a controlled trial of primary wound closure. *Arch Emerg Med*. 1988 Sep;5(3):156-61. doi: 10.1136/emj.5.3.156. PMID: 3178974; PMCID: PMC1285519.
- Tabaka ME, Quinn JV, Kohn MA, Polevoi SK. Predictors of infection from dog bite wounds: which patients may benefit from prophylactic antibiotics? *Emerg Med J*. 2015 Nov;32(11):860-3. doi: 10.1136/emered-2014-204378. Epub 2015 Jan 29. PMID: 25634096.

Photo Credit

- AliEM Cobblestoning: <https://www.aliem.com/pem-pocus-series-soft-tissue-ultrasound/figure-5-cellulitis-cobblestone-stones/>
- Trauma illustrated: <https://www.gponline.com/trauma-illustrated/article/1443888>